

---

# Upper-molar intrusion using anterior palatal anchorage and the ‘Mini-Mousetrap’ appliance

Benedict Wilmes,\* Thomas Niegel† and Dieter Drescher\*

Department of Orthodontics, University of Duesseldorf, Duesseldorf\* and Private Prac-tice, Bochum,† Germany

The intrusion of over-erupted upper molars is an orthodontic problem of major difficulty. When conventional appliances are used, the extrusion of adjacent teeth is likely. However, in recent years, temporary anchorage devices have been used to avoid unwanted side effects. For this purpose, mini-implants have primarily been inserted in the alveolar process. However, due to many disadvantages associated with mini-implant placement between the roots of the upper molars, it is now preferred to insert mini-implants in the anterior palate, which ensures a low risk of failure or mini-implant fracture.

The ‘Mini-Mousetrap’ appliance (without a TPA) was designed as a less bulky alternative to the ‘Mousetrap’ (with a TPA), and is comprised of two mini-implants in the anterior palate and attached lever arms for molar intrusion. If a TPA is not used, molar movement must be monitored and the direction of the force adjusted to avoid unwanted molar tipping.

(Aust Orthod J 2018; 34: 263-267)

Received for publication: February 2018

Accepted: September 2018

Benedict Wilmes: wilmes@med.uni-duesseldorf.de; Thomas Niegel: niegel@t-online.de; Dieter Drescher: drescher@med.uni-duesseldorf.de

## Introduction

Upper molars often over-erupt when there are missing lower molars. To accomplish prosthodontic rehabilitation in the mandibular arch, it is desirable to intrude the over-erupted upper molars, which often cause the adjacent teeth to extrude when conventional multibracket appliances are used. In recent years, temporary anchorage devices (TADs) have provided clinicians with a mechanism to overcome these disadvantages while avoiding unaesthetic full-appliance therapy.<sup>1-6</sup>

To avoid tipping of the molars as intrusion occurs, forces must be applied buccally and palatally or a transpalatal arch placed to support the teeth. Mini-plates inserted into the zygomatic buttress may be employed from which to deliver a buccal force to achieve molar intrusion;<sup>3,4,7-9</sup> however, their placement requires a surgical procedure and the exposure of bone. The insertion of larger mini-implants in the zygomatic buttress is a surgical alternative but a less advisable possibility, since coverage of the insertion site by movable mucosa increases the risk of screw failure and soft-tissue irritation.<sup>10,11</sup> A third alternative

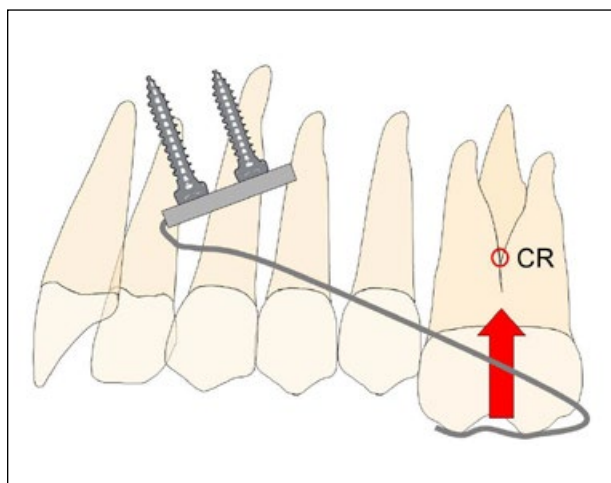
is to insert mini-implants in the alveolar process,<sup>1,2,5,12</sup> but the disadvantages of placement between the roots of the upper molars include:

- In many cases, there is insufficient space on the buccal aspect to insert a mini-implant safely between the molar roots.<sup>13-15</sup> Narrower implants carry a higher risk of fracture<sup>16</sup> and failure.<sup>17,18</sup>
- The soft tissue is often thicker on the palatal side of the alveolar process,<sup>19</sup> necessitating a longer lever arm that increases the likelihood of mini-implant tipping and failure.<sup>17</sup>
- Contact between a mini-implant and a dental root may cause damage to periodontal structures and possibly lead to failure.<sup>20,21</sup>
- A molar moved against a mini-implant during intrusion will cease to move, and the root surface may be damaged.<sup>22,23</sup>
- When a mini-implant is inserted in the posterior area of the upper alveolar process, there is a risk of penetration into the maxillary sinus.<sup>24</sup>

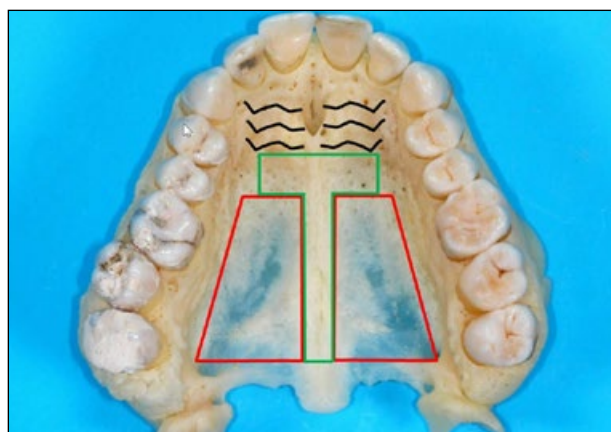
In a consideration of these problems, it is preferable to insert mini-implants away from the roots of the teeth

likely to be moved. The anterior palate offers a location of high bone quality, thin soft tissues, and nearly no risk of dental interference or root damage, which allows the insertion of mini-implants with a very high success rate.<sup>25</sup> Mini-implants have been used in the anterior palate in combination with a lever arm.<sup>26,27</sup> Named a 'Mousetrap', this appliance generates upper-molar intrusion and is combined with a transpalatal arch (TPA) to avoid palatal molar tipping. However, the placement of a TPA may reduce patient comfort and so the need for a TPA in every patient who needs upper molar intrusion is questioned.

In the present paper, a down-sized palatal appliance named the 'Mini-Mousetrap' is described. The appliance includes the use of two mini-implants in the anterior palate and a lever arm to the occlusal surface of the molar to be intruded (Figure 1).



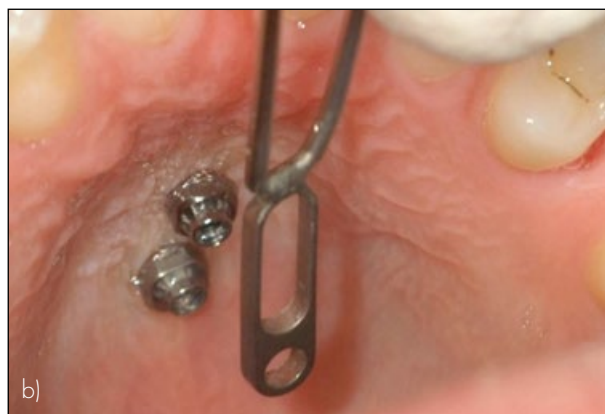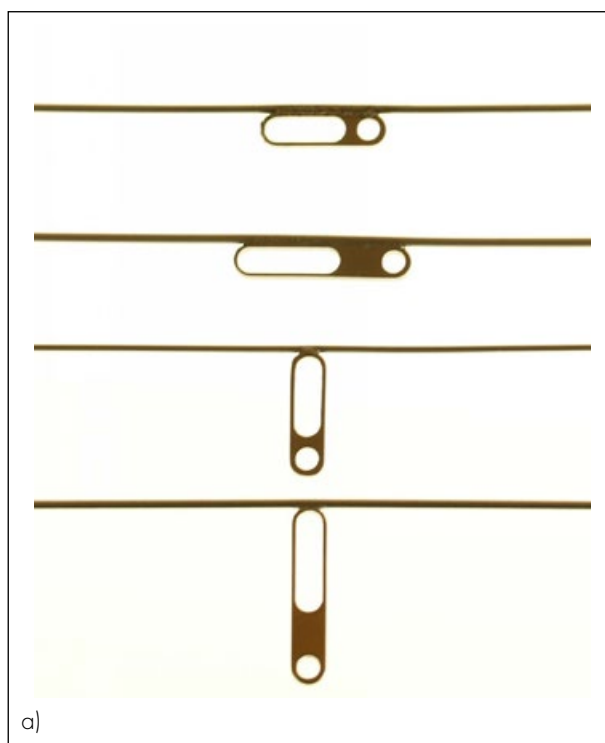
**Figure 1.** 'Mini-Mousetrap' appliance design and mechanics: A lever arm is connected to a palatal plate, anchored by two mini-implants in the anterior palate. The centre of resistance of the molar should be considered three-dimensionally to avoid unwanted tooth movement.



**Figure 2.** T-Zone: Recommended insertion site posterior to the palatal rugae. Bone is too thin in posterior and lateral areas.

### The 'Mini-Mousetrap' appliance

The 'Mini-Mousetrap' is anchored in the preferred T-Zone (Figure 2) of the anterior palate<sup>28</sup> by two mini-implants (2 × 9 mm), which may be inserted in the midline or para-median. A lever arm extends from a miniplate to the molar region. A Beneplate<sup>29</sup> (Figure 3a) has an incorporated 0.032" stainless steel (or β-Titanium) wire that is adapted to the mini-implants (Figure 3b), to the curvature of the palate, and the occlusal surface of the molar to function as the lever arm. By activating the lever arm upwards, a constant intrusive force is produced (Figure 1).



**Figure 3.** Beneplate system: Long and short Beneplates (a) with wires in place (0.032") at the long side (for paramedian insertion) and at the short side of the plate (for median insertion). Fixation of a Beneplate on top of two mini-implants (b).

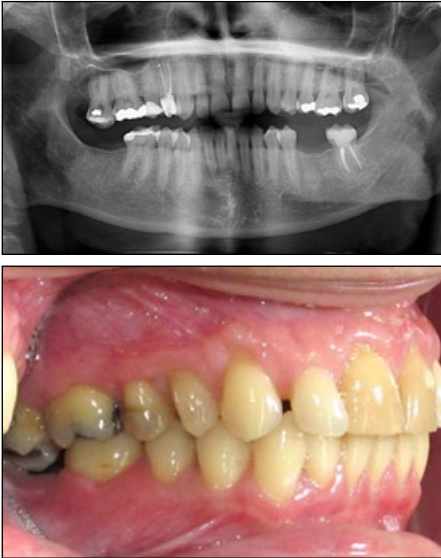

Figure 4. 42-year-old female with an over-erupted upper right second molar.

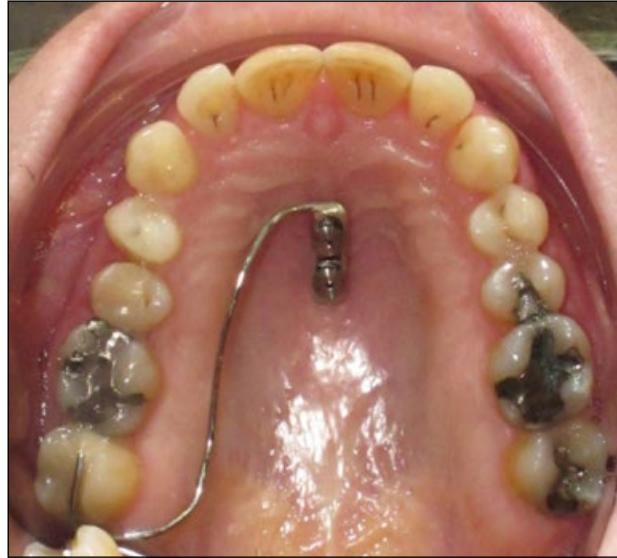
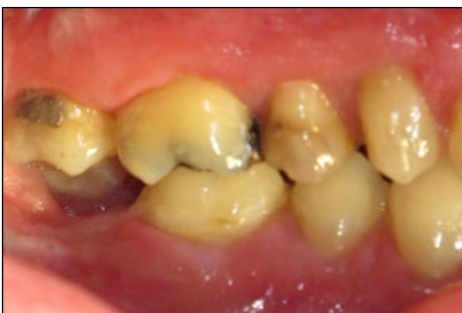
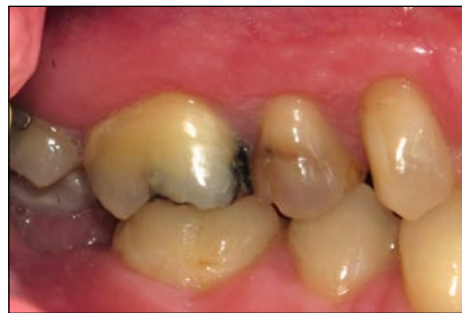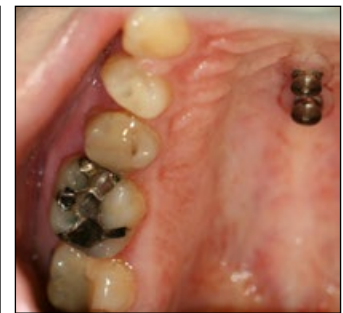Figure 5. 'Mini-Mousetrap' in place: Two mini-implants connected to a Beneplate with a wire in place.



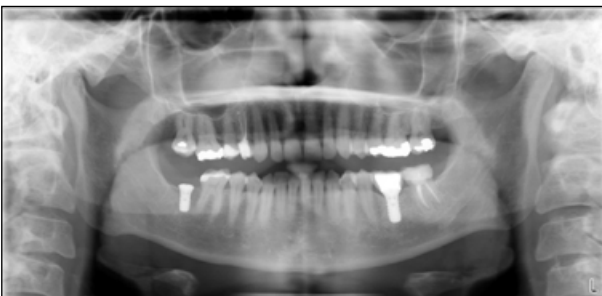a)



b)



c)



d)

Figure 6. Intrusion of the molar after six (a) and nine (b-d) months.

### Case 1

A 42-year-old female was referred by her general dentist for the intrusion of an over-erupted upper right second molar, in preparation for the placement of a dental implant in the edentulous lower right molar region (Figure 4). Two mini-implants were inserted in the middle of the anterior palate for the subsequent attachment of a Beneplate with a lever wire in place. A molar intrusion force of approximately 100 gm

was activated (Figure 5). Successful intrusion of the molar was achieved and recognisable after six and nine months, respectively (Figure 6), so that the patient was ready for prosthodontic rehabilitation (Figure 7).

### Case 2

A 38-year-old female patient was referred by her general dentist for the intrusion of an over-erupted upper left second molar. A dental implant had already been placed in the missing lower left second-molar site, but there was inadequate space for the placement of an upper molar crown (Figure 8). Two mini-implants

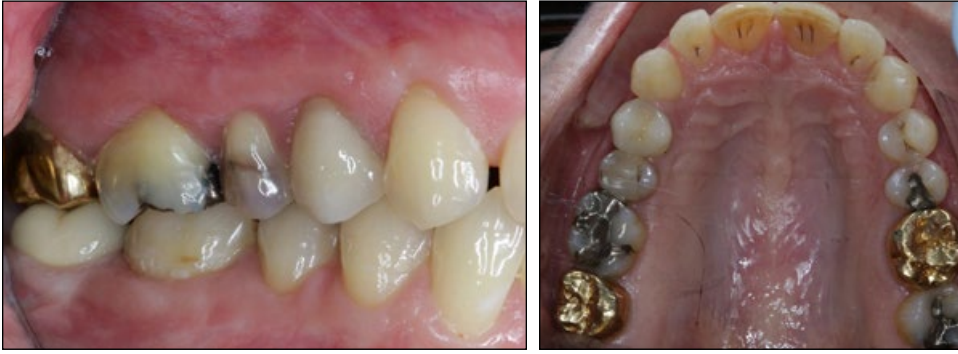

Figure 7. Patient after prosthodontic restoration.

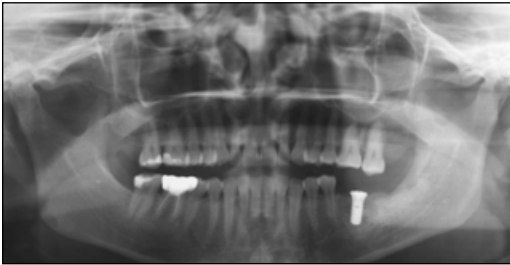

Figure 8. A 38-year-old female patient with an over-erupted upper left second molar.

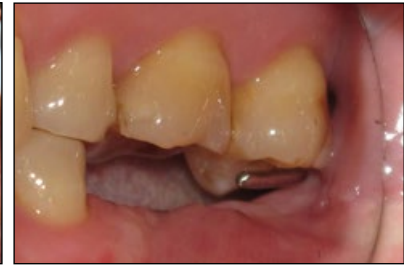
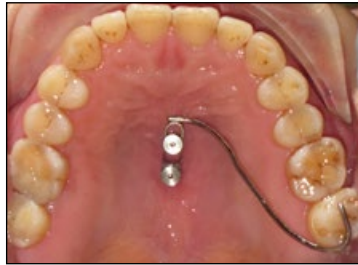
Figure 9. 'Mini-Mousetrap' in place with two median mini-implants in the palate palate and a Beneplate with a 0.032" wire serving as an intrusion lever arm.

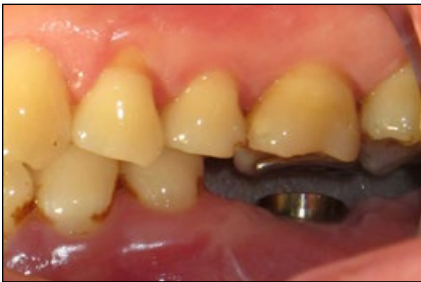

Figure 10. Modified lever arm for an additional slight intrusion of the first upper molar.

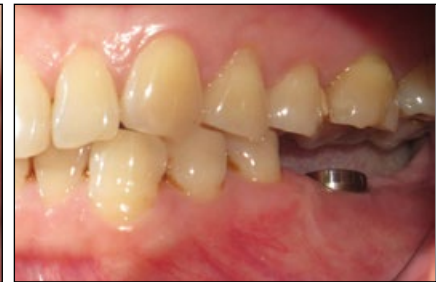
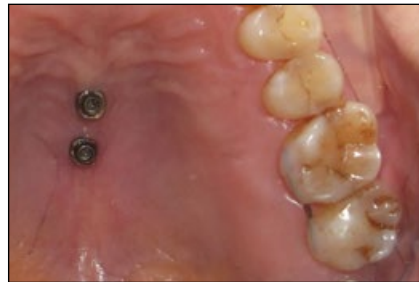
Figure 11. Both upper left molars are corrected.

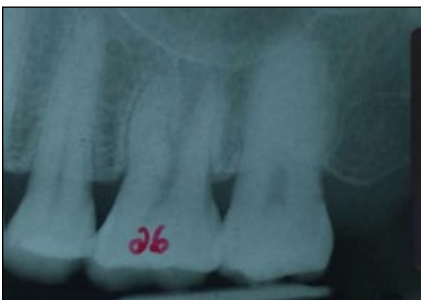
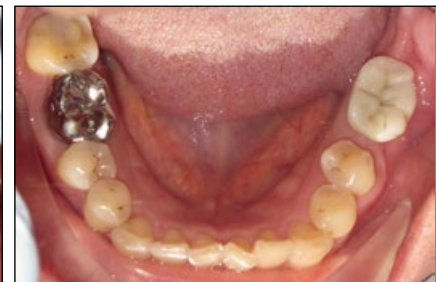
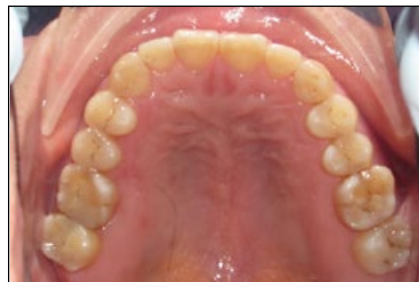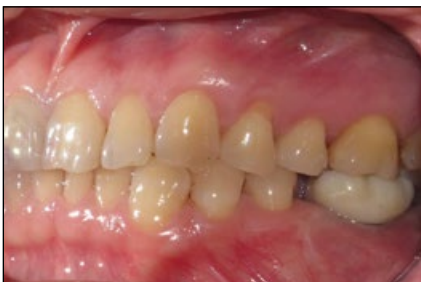Figure 12. Patient after prosthodontic treatment.

were inserted in the midline of the anterior palate, and a Beneplate with an incorporated 0.032" stainless steel wire was adapted and fixed to the mini-implants by micro-screws. Subsequently, an intrusive force of approximately 100 gm was activated and applied (Figure 9). After six months, the second molar had been intruded by 3 mm. The lever arm was modified and maintained for another three months as the referring dentist asked for slight additional intrusion of the first upper molar as well (Figure 10). Three months later, both molars were corrected (Figure 11) and a prosthodontic crown was placed on the lower dental implant (Figure 12).

## Conclusion

The 'Mini-Mousetrap' proved to be a reliable device for the intrusion of over-erupted molars.

The design is less bulky compared with the original Mousetrap appliance, which incorporated a TPA. However, movement of the molars should be monitored carefully, and the lever arm must be adjusted as necessary. Its anchorage in the anterior palate ensures a low risk of failure or mini-implant fracture.

## References

1. Kravitz ND, Kusnoto B, Tsay PT, Hohlt WF. Intrusion of overerupted upper first molar using two orthodontic miniscrews. A case report. *Angle Orthod* 2007;77:915-22.
2. Kravitz ND, Kusnoto B, Tsay TP, Hohlt WF. The use of temporary anchorage devices for molar intrusion. *J Am Dent Assoc* 2007;138:56-64.
3. Yao CC, Lee JJ, Chen HY, Chang ZC, Chang HF, Chen YJ. Maxillary molar intrusion with fixed appliances and mini-implant anchorage studied in three dimensions. *Angle Orthod* 2005;75:754-60.
4. Sherwood KH, Burch JG, Thompson WJ. Closing anterior open bites by intruding molars with titanium miniplate anchorage. *Am J Orthod Dentofacial Orthop* 2002;122:593-600.
5. Lin JC, Liou EJ, Yeh CL. Intrusion of overerupted maxillary molars with miniscrew anchorage. *J Clin Orthod* 2006;40:378-83; quiz 358.
6. Wilmes B. Fields of Application of Mini-Implants. In: Ludwig B, Baumgaertel S, Bowman J, eds. *Innovative Anchorage Concepts. Mini-Implants in Orthodontics*. Berlin, New York: Quintessenz, 2008.
7. Erverdi N, Keles A, Nanda R. The use of skeletal anchorage in open bite treatment: a cephalometric evaluation. *Angle Orthod* 2004;74:381-90.
8. Umemori M, Sugawara J, Mitani H, Nagasaka H, Kawamura H. Skeletal anchorage system for open-bite correction. *Am J Orthod Dentofacial Orthop* 1999;115:166-74.
9. Moon CH, Wee JU, Lee HS. Intrusion of overerupted molars by corticotomy and orthodontic skeletal anchorage. *Angle Orthod* 2007;77:1119-25.
10. Cheng SJ, Tseng IY, Lee JJ, Kok SH. A prospective study of the risk factors associated with failure of mini-implants used for orthodontic anchorage. *Int J Oral Maxillofac Implants* 2004;19:100-6.
11. Tsaousidis G, Bauss O. Influence of insertion site on the failure rates of orthodontic miniscrews. *J Orofac Orthop* 2008;69:349-56.
12. Lee M, Shuman J. Maxillary molar intrusion with a single miniscrew and a transpalatal arch. *J Clin Orthod*;46:48-51.
13. Ludwig B, Glasl B, Kinzinger GS, Lietz T, Lisson JA. Anatomical guidelines for miniscrew insertion: Vestibular interradicular sites. *J Clin Orthod*;45:165-73.
14. Poggio PM, Incorvati C, Velo S, Carano A. "Safe zones": a guide for miniscrew positioning in the maxillary and mandibular arch. *Angle Orthod* 2006;76:191-7.
15. Kim SH, Yoon HG, Choi YS, Hwang EH, Kook YA, Nelson G. Evaluation of interdental space of the maxillary posterior area for orthodontic mini-implants with cone-beam computed tomography. *Am J Orthod Dentofacial Orthop* 2009;135:635-41.
16. Wilmes B, Panayotidis A, Drescher D. Fracture resistance of orthodontic mini-implants: a biomechanical in vitro study. *Eur J Orthod* 2011;33:396-401.
17. Wiechmann D, Meyer U, Büchter A. Success rate of mini- and micro-implants used for orthodontic anchorage: a prospective clinical study. *Clin Oral Implants Res* 2007;18:263-7.
18. Fritz U, Diedrich P. Clinical suitability of titanium microscrews for orthodontic anchorage. In: Nanda R, Uribe FA, eds. *Temporary anchorage devices in orthodontics*. St. Louis: Mosby Elsevier, 2009;287-94.
19. Ludwig B, Glasl B, Bowman SJ, Wilmes B, Kinzinger GS, Lisson JA. Anatomical guidelines for miniscrew insertion: palatal sites. *J Clin Orthod* 2011;45:433-41.
20. Miyawaki S, Koyama I, Inoue M, Mishima K, Sugahara T, Takano-Yamamoto T. Factors associated with the stability of titanium screws placed in the posterior region for orthodontic anchorage. *Am J Orthod Dentofacial Orthop* 2003;124:373-8.
21. Chen YH, Chang HH, Chen YJ, Lee D, Chiang HH, Yao CC. Root contact during insertion of miniscrews for orthodontic anchorage increases the failure rate: an animal study. *Clin Oral Implants Res* 2008;19:99-106.
22. Kadioglu O, Büyükyılmaz T, Zachrisson BU, Maino BG. Contact damage to root surfaces of premolars touching miniscrews during orthodontic treatment. *Am J Orthod Dentofacial Orthop* 2008;134:353-60.
23. Maino BG, Weiland F, Attanasio A, Zachrisson BU, Büyükyılmaz T. Root damage and repair after contact with miniscrews. *J Clin Orthod* 2007;41:762-6; quiz 750.
24. Gracco A, Tracey S, Baciliero U. Miniscrew insertion and the maxillary sinus: an endoscopic evaluation. *J Clin Orthod*;44:439-43.
25. Karagkiolidou A, Ludwig B, Pazera P, Gkantidis N, Pandis N, Katsaros C. Survival of palatal miniscrews used for orthodontic appliance anchorage: a retrospective cohort study. *Am J Orthod Dentofacial Orthop* 2013;143:767-72.
26. Wilmes B, Nienkemper M, Ludwig B, Nanda R, Drescher D. Upper-molar intrusion using anterior palatal anchorage and the Mousetrap appliance. *J Clin Orthod* 2013;47:314-20; quiz 328.
27. Wilmes B, Vasudavan S, Stocker B, Willmann JH, Drescher D. Closure of an open bite using the 'Mousetrap' appliance: a 3-year follow-up. *Aust Orthod J* 2015;31:208-15.
28. Wilmes B, Ludwig B, Vasudavan S, Nienkemper M, Drescher D. The T-Zone: Median vs. Paramedian Insertion of Palatal Mini-Implants. *J Clin Orthod* 2016;50:543-51.
29. Wilmes B, Drescher D, Nienkemper M. A miniplate system for improved stability of skeletal anchorage. *J Clin Orthod* 2009;43:494-501.