

# Maxillary molar intrusion using mini-implants in the anterior palate – “Mousetrap” versus “Mini-Mousetrap”

*Benedict Wilmes, Sivabalan Vasudavan, and Dieter Drescher*

Supra-erupted maxillary molar teeth pose a major restorative challenge when attempting to prosthetically rehabilitate a partially edentulous mandibular dental arch. Traditional approaches with conventional tooth-borne appliances usually entail undesirable side-effects, including extrusion of adjacent teeth. Temporary anchorage devices (TADs), often inserted in the alveolar process, should help to minimize this phenomenon. The interradicular placement of mini-implants positioned between the roots of the maxillary molars has a number of inherent disadvantages and limitations. The preferred site for insertion of mini-implants is the anterior palate, which ensures a low risk of failure and mini-implant fracture. The ‘Mousetrap’ appliance is comprised of two mini-implants in the anterior palate, with attached lever arms for molar intrusion and a transpalatal arch (TPA) to avoid unwanted palatal tipping of the molar to be intruded. The ‘Mini-Mousetrap’ appliance was designed as a pared-down version without a TPA. If a TPA is not used, molar movement must be closely monitored, and the line of force action may need modification in order to minimize unwanted molar tipping. (Semin Orthod 2020; ■:1–13) © 2020 Published by Elsevier Inc.

## Introduction

A common sequela following the loss of multiple mandibular molars is supraeruption of the antagonistic maxillary molars. The resultant reduced occlusal vertical dimension poses a challenge for any prosthetic rehabilitation of the mandibular edentulous ridge. The orthodontist is often requested to redress this situation by intruding the supra-erupted maxillary molars. Traditional approaches involving conventional fixed appliances, often lead to reciprocal extrusion of the adjacent teeth. In recent years, temporary anchorage devices (TADs) have provided clinicians with a biomechanical tool to overcome these

disadvantages, which can even make avoidance of unaesthetic full-appliance therapy possible.<sup>1-6</sup>

Absolute molar intrusion has long been considered the Holy Grail in orthodontic biomechanics. In order to obtain a pure molar intrusive tooth movement, it is necessary that the force line of action passes close or through the center of resistance (CR) of the tooth in all the three planes of space. The estimated CR of the upper molar in the horizontal plane coincides with the palatal root.<sup>7</sup> If the intrusive force is applied only at one side, a moment relative to the CR will be created and either buccal or palatal tipping may be observed clinically. To prevent this adverse effect, forces must be applied both buccally and lingually relative to the CR. A transpalatal arch (TPA) can be helpful to counteract this undesirable phenomenon. Mini-plates inserted into the zygomatic buttress may be employed for delivery of a buccal intrusive force in order to achieve molar intrusion.<sup>3,4,7-9</sup> However, surgical placement of a titanium bone fixation plate requires flap elevation and full exposure of the underlying alveolar bone. Insertion of mini-implants with greater dimensions in

*Department of Orthodontics, University of Duesseldorf, Moor-enstr. 5, 40225 Duesseldorf, Germany; Orthodontics on St Quentin, Suite 9, 40 St Quentin Avenue, Claremont, WA 6010, Australia.*

*Corresponding address: Dr. Benedict Wilmes, Department for Orthodontics, University of Duesseldorf, D-40225 Duesseldorf, Germany. Tel: +49 211 8118160. E-mail: Wilmes@med.uni-duesseldorf.de*

© 2020 Published by Elsevier Inc.  
1073-8746/12/1801-\$30.00/0

<https://doi.org/10.1053/j.sodo.2020.01.003>

the zygomatic buttress is also a viable option, but the implant will need to be placed in unattached mucosa. Potential drawbacks of mini-implant placement in unattached mucosa are a higher failure rate for retention, and possible soft tissue irritation causing discomfort and pain.<sup>10,11</sup>

A third alternative site of placement of mini-implants is within the alveolar process.<sup>1,2,5,12</sup> However, there are several inherent disadvantages of insertion in the interradicular area of the maxillary molar teeth:

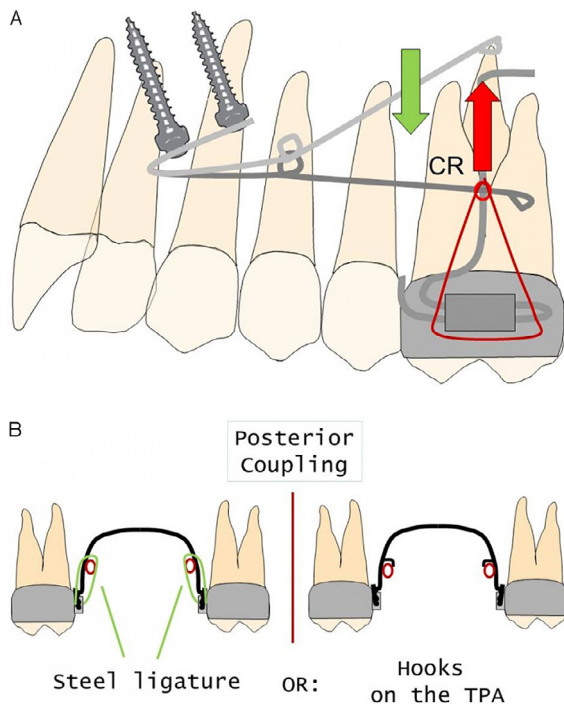
- insufficient space on the buccal aspect to insert a mini-implant safely between the molar roots.<sup>13-15</sup> Trying to solve this problem by placing a narrow

diameter implants potentiates a higher risk of fracture<sup>16</sup> and subsequent failure.<sup>17,18</sup>

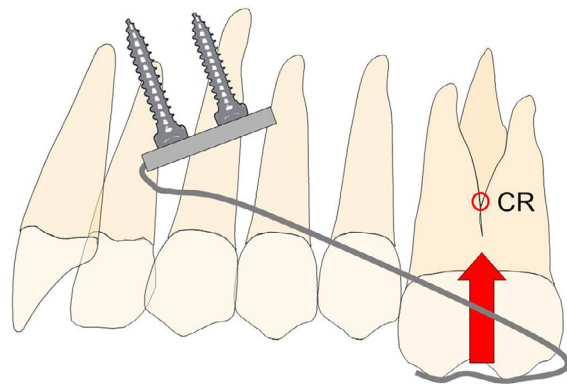
- a thicker soft tissue on the palatal side of the alveolar process,<sup>19</sup> necessitating a longer lever arm which increases the likelihood of mini-implant tipping and failure.<sup>17</sup>
- contact between a mini-implant and a dental root may cause damage to periodontal structures and possibly lead to failure.<sup>20,21</sup>
- a molar colliding with a mini-implant during intrusion may cause root surface damage.<sup>22,23</sup>
- the risk of penetrating the maxillary sinus, when a mini-implant is inserted in the posterior area of the upper alveolar process.<sup>24</sup>

In order to minimize these risks, a prudent overarching strategy is placement of mini-implants safely away from both the roots and the intended path of tooth movement. The anterior palate is an adequate alternative insertion site, where mini-implants with larger dimensions can be safely placed with a higher degree of retention and stability.<sup>25</sup> Mini-implants have been used in the anterior palate in combination with a lever arm. Aptly described as a 'Mousetrap' (Fig. 1A,B), this appliance generates an intrusive movement on the upper molars with only minimal palatal tipping, if combined with a TPA. The 'Mousetrap' has been used for intrusion of overerupted molars in pre-prosthetic patients<sup>26</sup> and for maxillary molar intrusion in anterior open bite cases.<sup>27</sup>

However, the placement of a TPA may compromise overall patient comfort, and in some cases, may not be tolerated at all. The routine usage of a TPA for every patient who requires



**Figure 1.** Design of the mousetrap appliance: A: One or two lever arms are connected to two mini implants inserted in the anterior palate. In the deactivated state, the distal ends of the lever arms are located apically. By pulling the lever arms downward and connecting them to the molars, a constant intrusive force is produced. The center of resistance (CR) of the molars must be considered for force application especially in the sagittal dimension, while a TPA is used to avoid unwanted tooth movement in the transversal orientation. B: Options for the posterior connection of the intrusion lever arms to the molars: Using steel ligatures (left) or soldering hooks on the TPA used as a stop for the lever arm (right).




**Figure 2.** Design of the mini-mousetrap appliance. Given that a TPA is not used, the CR of the molar must be considered in sagittal and transversal orientations.

maxillary molar intrusion may be questioned. An alternative for consideration, is a pared-down variation of the palatal appliance without a TPA named the 'Mini-Mousetrap' (Fig. 2).

### Clinical procedure

The "Mousetrap" and the 'Mini-Mousetrap' appliances are anchored in the anterior palate distally from the rugae (T-Zone)<sup>28</sup> on two mini-implants (2 × 9 mm, Benefit, PSM, La Quinta, CA, USA), which may be inserted in the midline or in a paramedian configuration (Fig. 3A).<sup>29</sup> A lever arm extends from the TAD-anchored miniplate to the molar region (Fig. 3B). A Beneplate<sup>30</sup> (Fig. 3B) which has

an incorporated 0.032" stainless steel (or  $\beta$ -Titanium) wire is fixed to the mini-implants with small fixing screws (Fig. 3c). If the mini-implants are not inserted perfectly in parallel, the Beneplate body can be easily adapted using a three-pronged plier. Activation of the Mousetrap appliance occurs by pulling the lever arms downward and connecting them to the molars, which produces a constant intrusive force. A force gauge can be used to measure the level of the applied intrusive. Our clinical protocol includes the application of an approximate intrusive force of less than 100 grams per side. If bodily intrusion is indicated, the line of force action should be coincidental with the CR of the molars. Simultaneous intrusion and uprighting of molars can be



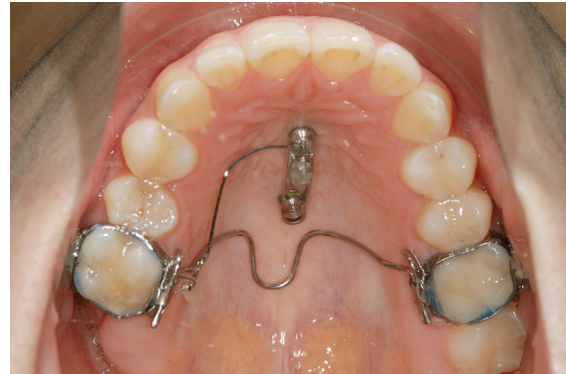**Figure 3.** Mini-Implant anchorage unit: A: Head of a Benefit mini-implant with an inner screw thread. B: Normal and wide Beneplates with wires (0.032") in place for paramedian (upper) and median (lower) mini-implant insertion. C: Fixing screw. D: Impression cap and E: Laboratory analogue.

achieved by changing the line of force action more mesially or distally from the CR. (Fig. 1). In the posterior region, the intrusive force can be applied by two different options: 1. Using a steel ligature, or by soldering a hook on the TPA to be used as a stop for the lever arm (Fig. 1B). The Beneplate can either be adapted chairside immediately after mini-implant insertion or indirectly on a plaster model. Impression caps (Fig. 3D) and laboratory analogues were used (Fig. 3E) for the clinical cases presented.

### *Clinical examples with the 'Mousetrap'*

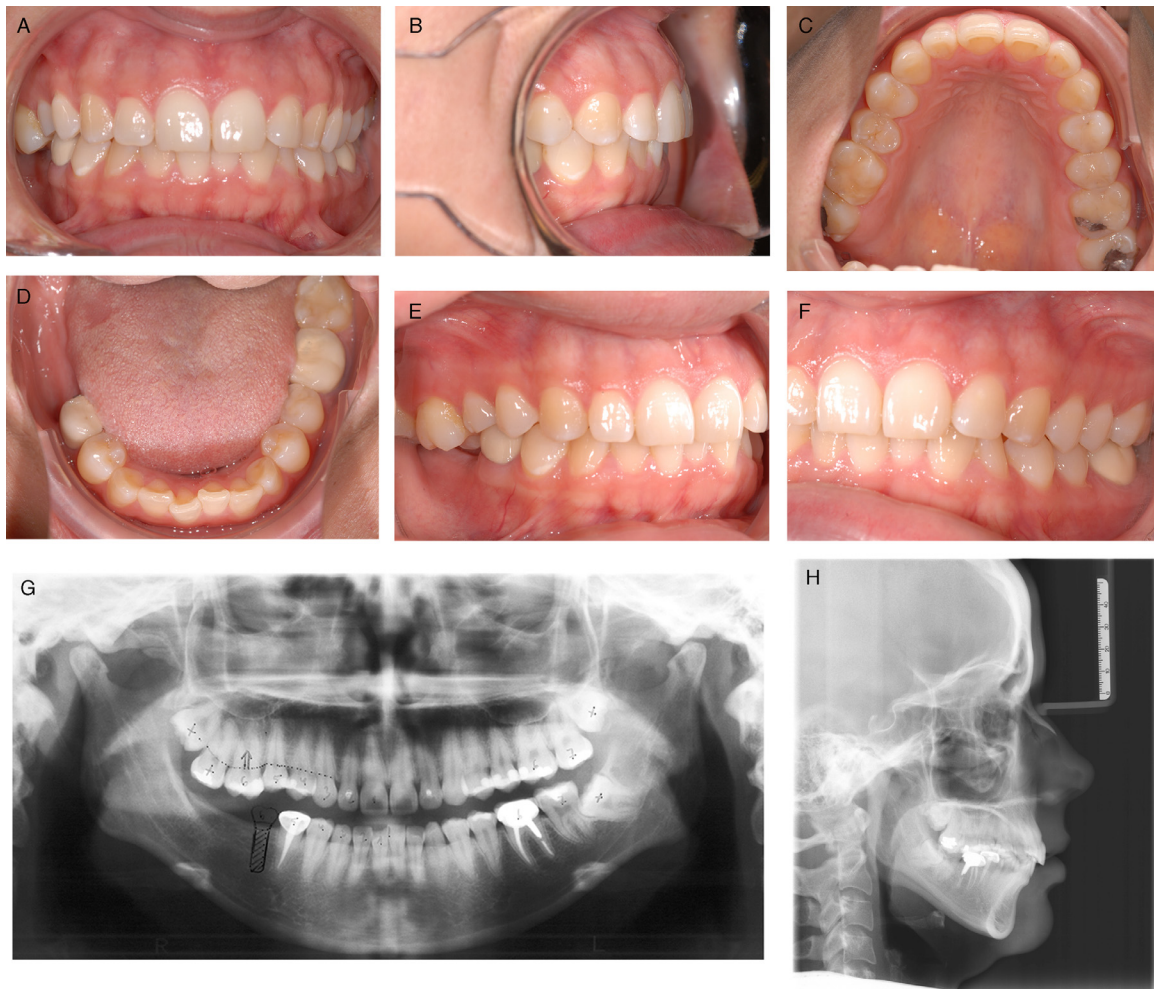#### **Case 1**

The treatment protocol of a 25-year-old adult female patient with a supra-erupted maxillary right first molar is illustrated. The patient was

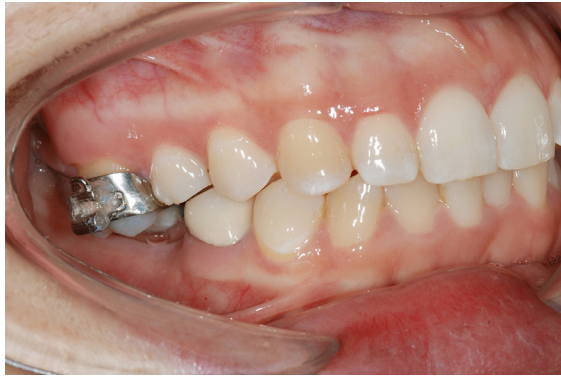

**Figure 5.** Case 1: Mousetrap mechanics in-situ.

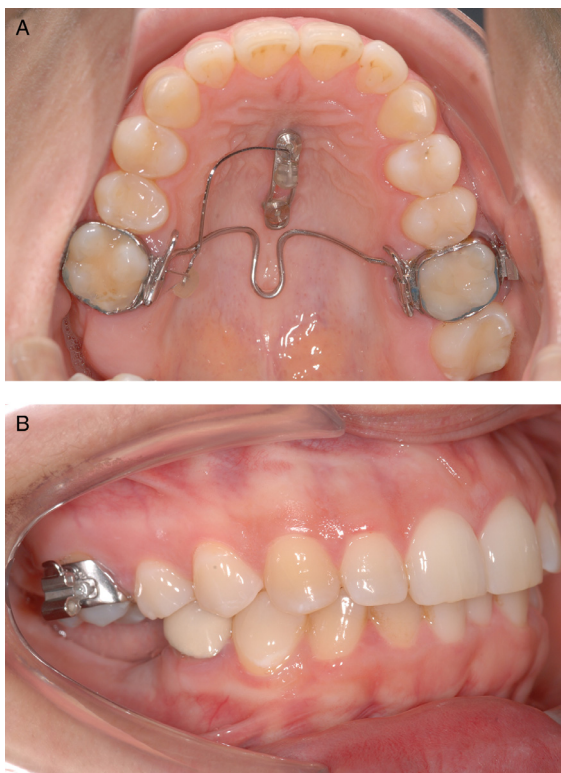
referred from her general dentist only for intrusion of the overerupted maxillary molar; the patient elected not to receive comprehensive



**Figure 4.** Case 1: 25-year-old female patient with a supra-erupted maxillary right first molar, resulting in insufficient occlusal vertical space for prosthodontic rehabilitation of the edentulous area of the right mandible.

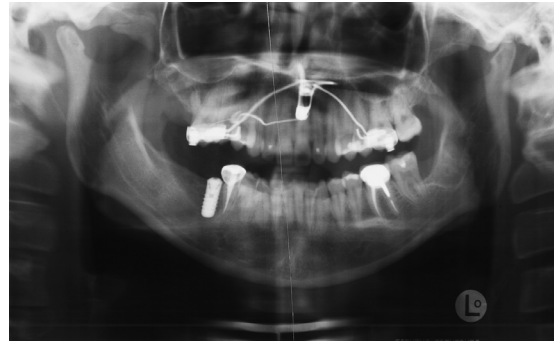


**Figure 6.** Case 1: Lateral photographs.



**Figure 7.** Case 1: Intraoral occlusal relationship after six months of treatment with successful intrusion of the maxillary right molar.

treatment to resolve the lower incisor irregularity. The subsequent restorative plan entailed the placement of an osseointegrated implant in the

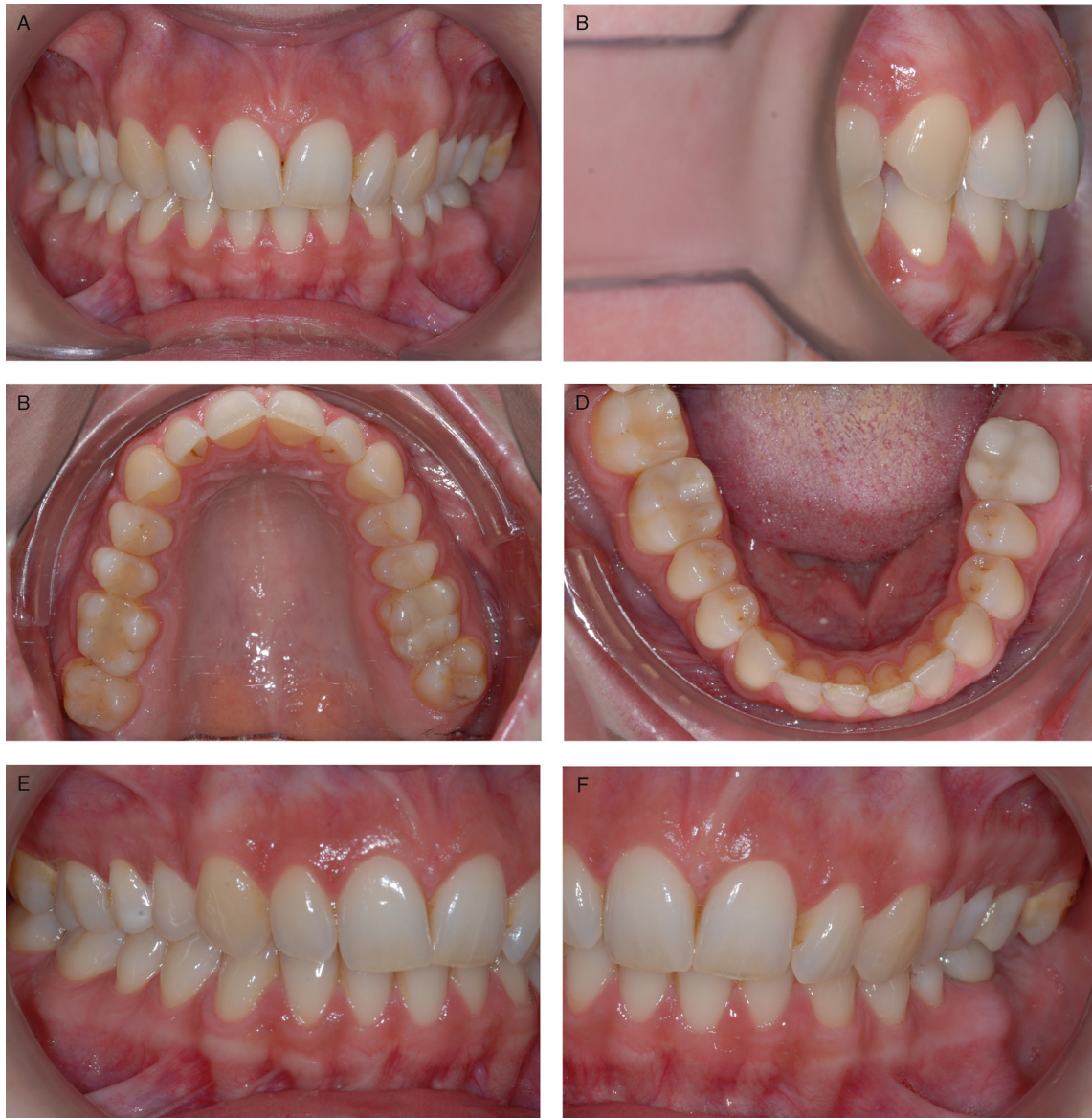

**Figure 8.** Case 1: Panoramic radiograph after six months of treatment.

mandibular right molar region (Fig. 4A-H). After insertion of two mini-implants and adaption of two molar bands, the Beneplate was attached to the mini-implants and an intrusive force was applied to the overerupted right first molar (Figs. 5,6 A,B). After six months of treatment, the molar was sufficiently intruded to facilitate the planned restorative treatment (Figs. 7A-D, 8). In the meantime, osseointegration of the dental implant had occurred and the prosthodontic restoration was inserted (Fig. 8).

## Case 2

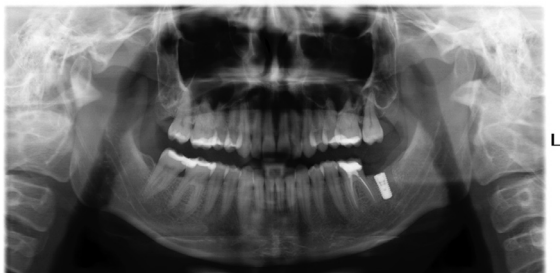The treatment protocol of a 26-year-old female patient with a supra-erupted maxillary left second molar is illustrated. The patient was referred from her general dentist for intrusion of the molar (Fig. 9A-F). An osseointegrated dental implant had previously been surgically positioned in the lower left molar region (Fig. 10), but was not able to be prosthetically restored due to the supraerupted maxillary molar and insufficient occluso-vertical dimension (Fig. 11). After insertion of two mini-implants and adaption of two molar bands on the upper right first and the left second molar, the Beneplate was adjusted and secured to the mini-implants. A TPA, with a small hook serving as a stop for the lever arm, was inserted (Fig. 12). After five months of active treatment, the maxillary molar had been intruded



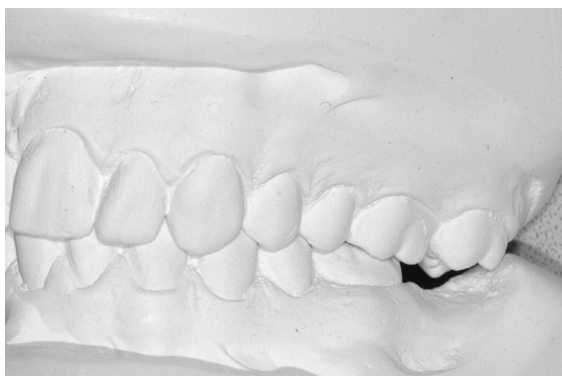**Figure 9.** Case 2: 26-year-old female patient with a supra-erupted maxillary left second molar.

approximately 2 mm (Figs. 13,14), but the prosthodontist requested further intrusion. Two months later, the maxillary left second molar was even over-intruded (Figs. 15,16). The dental implant (Fig. 17A,B) was restored with a

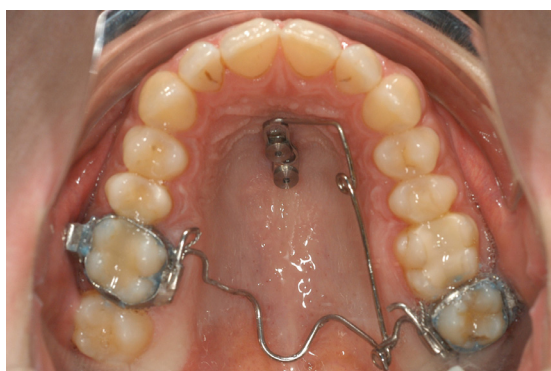
ceramic crown. At the four-month follow-up examination, spontaneous vertical eruption of the maxillary molar had occurred, and occlusal contact with the antagonistic tooth in the mandibular dental arch was present (Fig. 18A,B).



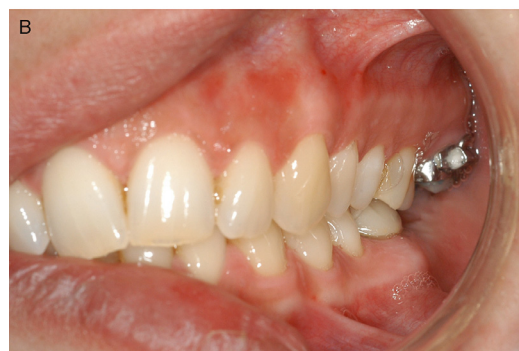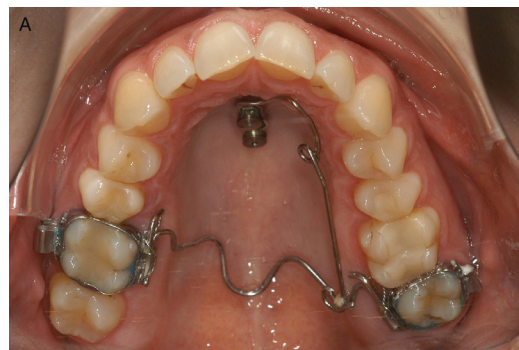**Figure 10.** Case 2: Panoramic radiograph: An osseointegrated dental implant had previously been surgically positioned in the lower left molar region but was not able to be prosthetically restored due to the overerupted maxillary molar and insufficient occlusal vertical dimension.



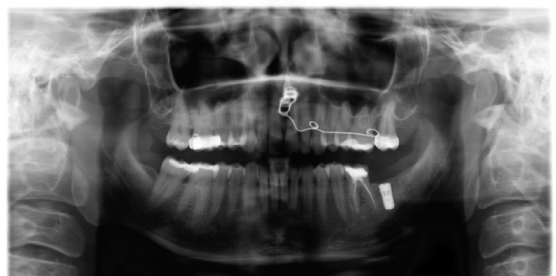**Figure 11.** Plaster models denoting the reduced occlusal vertical dimension for prosthetic rehabilitation of the dental implant.



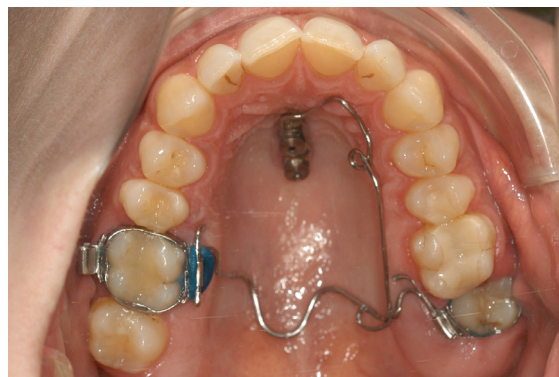**Figure 12.** Case 2: Mousetrap mechanics. A Beneplate with a 0.032" ss wire is adjusted and secured on top of the mini-implants. A TPA with a small hook serves as a stop for the lever arm.



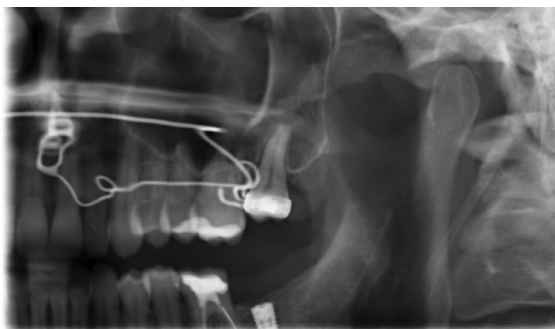
**Figure 13.** Case 2: After five months of treatment, the molar is intruded approximately by 2 mm.



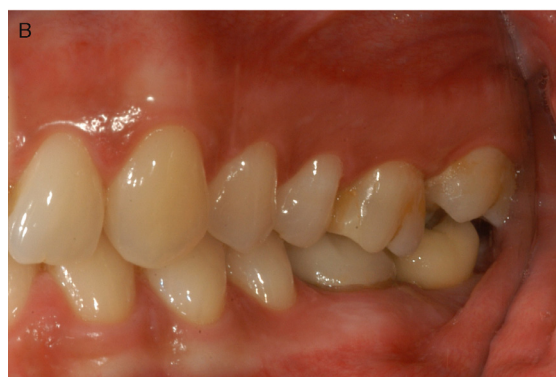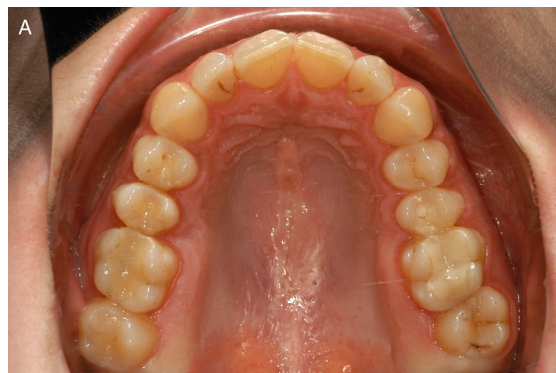**Figure 14.** Case 2: Panoramic radiograph after five months.



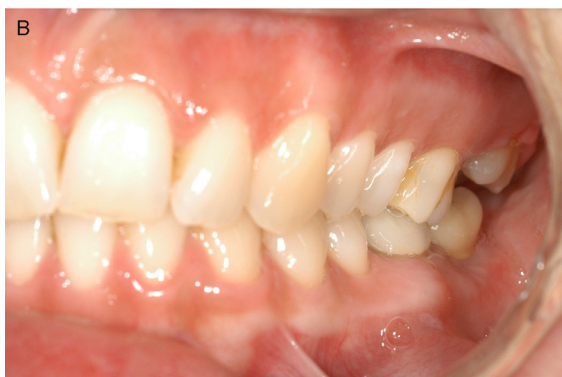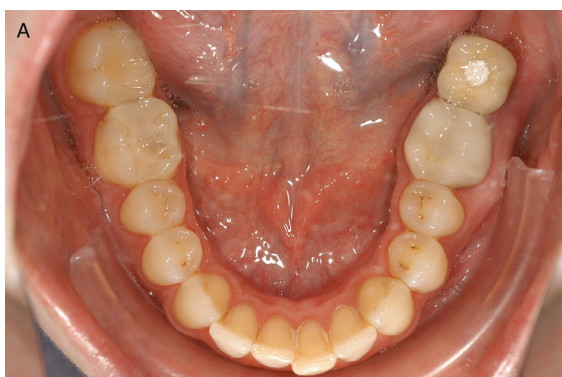
**Figure 15.** Case 2: After seven months of treatment, the maxillary left second molar is intruded with distinctive overcorrection.



**Figure 16.** Case 2: Panoramic radiograph after seven months.



**Figure 18.** Case 2: After four months spontaneous relapse of the over-intrusion has occurred.

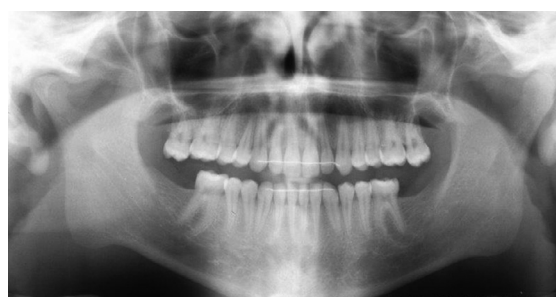

**Figure 17.** Case 2: After insertion of the implant-borne restoration.

### *Clinical examples with the 'Mini-Mousetrap'*

#### **Case 3**

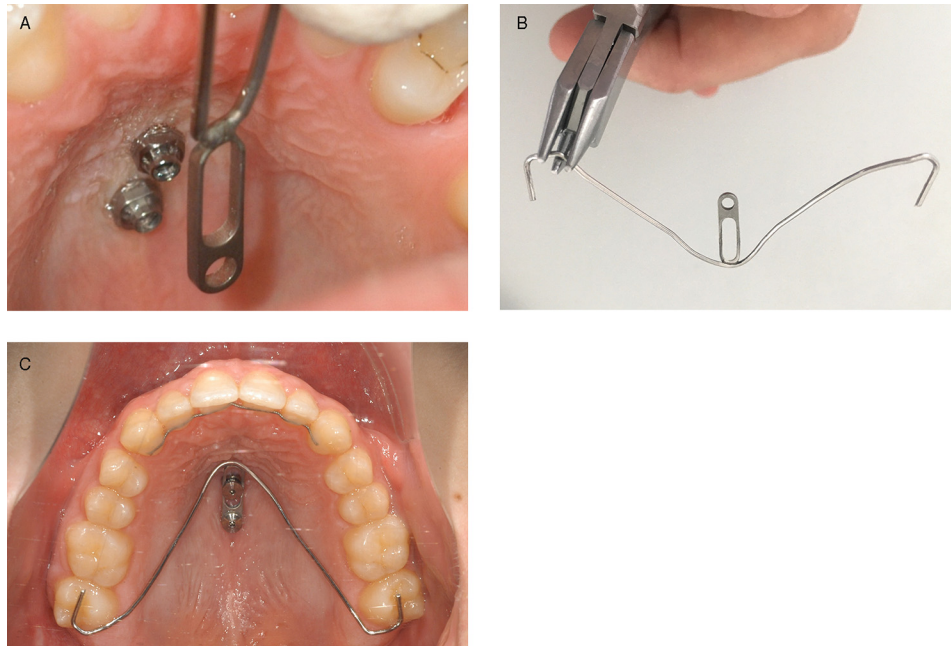A 19-year-old patient presented with bilateral supra-eruption of the upper second molars due to absence of the mandibular second molars (Fig. 19).



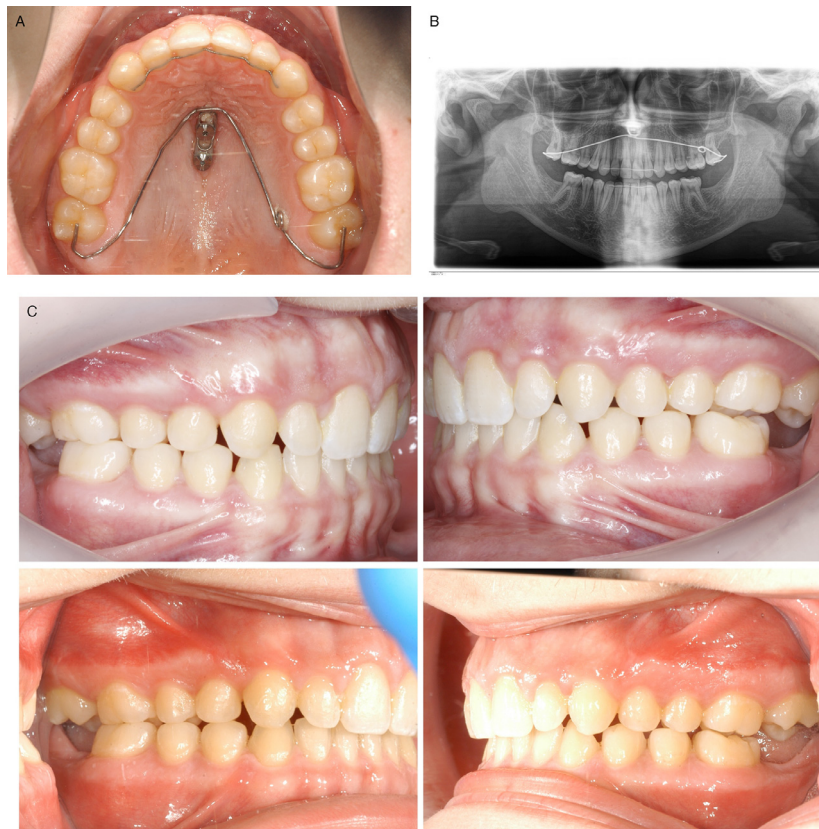
**Figure 19.** Case 3: Panoramic radiograph of a 16-year-old male patient with supra-erupted maxillary second molars.

After insertion of two mini-implants, a Beneplate with 0.8 mm wire was adapted chairside. The intrusion lever arms were inserted during the same appointment (Fig. 20). After five months, the maxillary molars were intruded approximately 2mm and the intended treatment goal was achieved (Fig. 21).

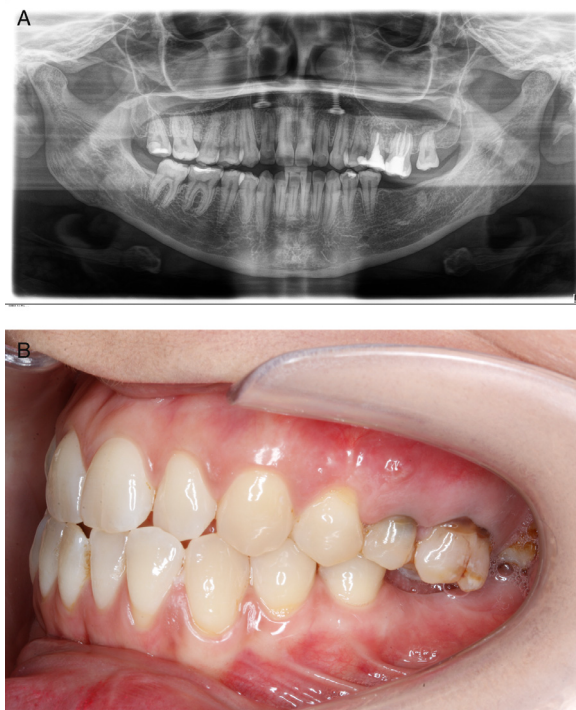




**Figure 20.** Case 3: The Beneplate was adapted and adjusted chairside immediately after median insertion of two mini-implants (A,B) and secured with two fixing screws (C).



**Figure 21.** Case 3: Intraoral situation (A) and OPG (B) after five months. Lateral views before and after intrusion of upper second molars (C).



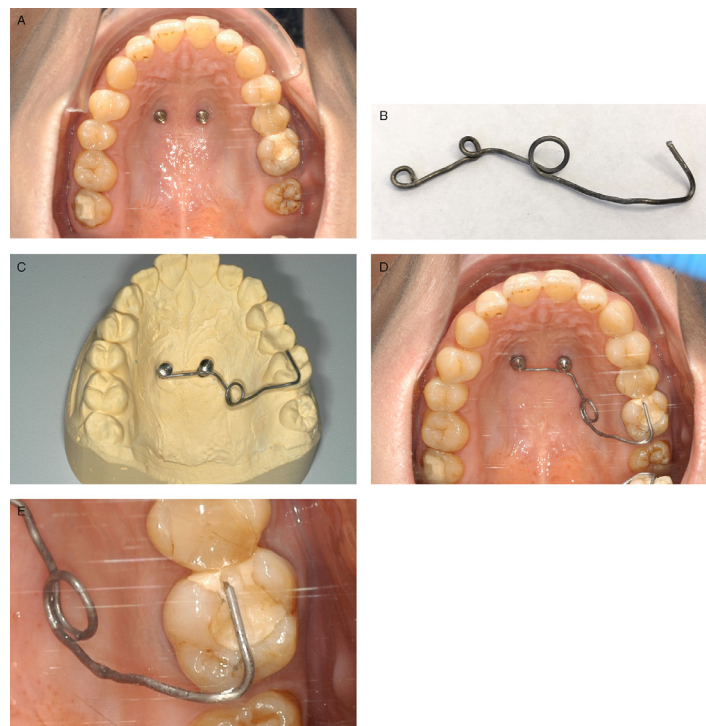
**Figure 22.** Case 4: 32-year-old female patient with a supra-erupted left maxillary first molar.

#### Case 4

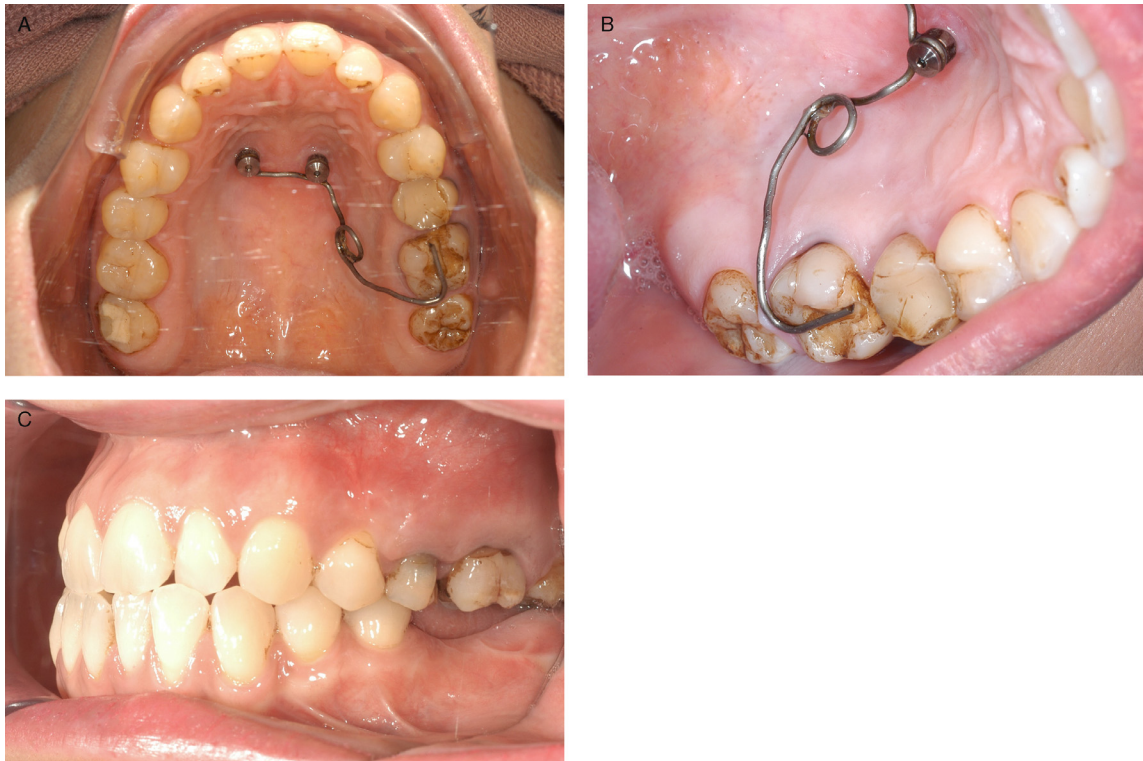
The second example illustrates treatment of a 32-year-old female patient with an over-erupted maxillary left first molar (Fig. 22), resulting from the premature loss of the mandibular left molar. After insertion of two paramedian mini-implants, a 0.8mm TMA wire (instead of a Beneplate) was bent, adapted, and secured to the mini-implants (Fig. 23). After four months, the maxillary left first molar had been intruded by approximately 2mm (Fig. 24), and after a further three months, total intrusion approximated 3.5 mm (Fig. 25, 26). Minor distal tipping of the maxillary left first molar is noted, which may occur when the TPA is not utilized and the line of action of the intrusive force is not adequately considered.

#### Discussion

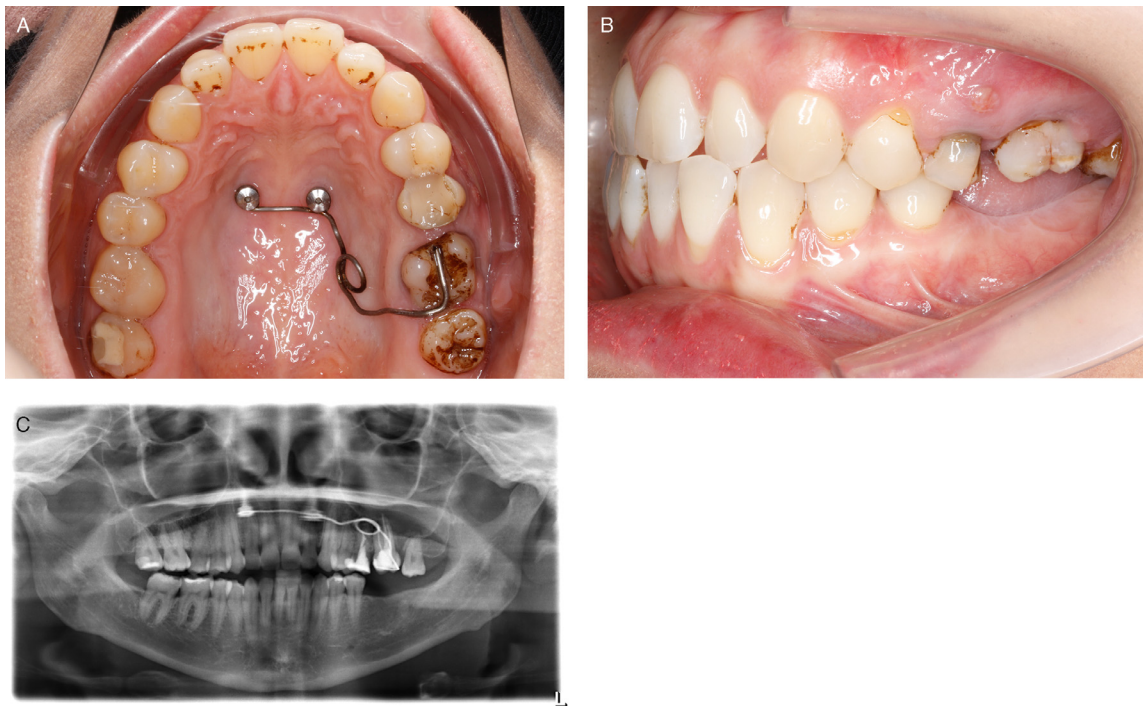
Supra-erupted maxillary molars often require intrusion to facilitate prosthodontic rehabilitation of missing teeth in the mandibular arch. The Mouse-trap appliance offers the following advantages over other contemporary TAD-based appliances:



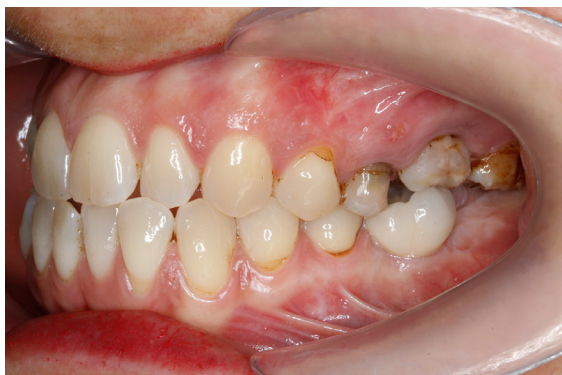**Figure 23.** Case 4: After insertion of two paramedian mini-implants (A) an impression was taken and an intrusion lever arm (0.032" TMA wire) was bent on a plaster model (B,C) and fixed on the two mini-implants (D). Grinding a small groove in the molar to be intruded, can help to improve retention, especially in presence of a failing restoration which needs to be renewed (E).



**Figure 24.** Case 4: Intraoral situation after four months: The maxillary left first molar has been intruded by approximately 2 mm.



**Figure 25.** Case 4: After a total treatment time of seven months the maxillary left first molar has been intruded by approximately 3.5 mm. Note slight distal tipping.



**Figure 26.** Case 4: Intraoral situation after prosthodontic restoration.

- a biomechanical approach with reliable determination of the point of force application, the direction of the line of the force applied, and the magnitude of the force applied. A constant force can be delivered that is measurable and easily modified during the progress of treatment.
- low surgical invasiveness
- no risk of penetration of the maxillary sinus
- no risk of root damage at the time of insertion of the mini-implant or during molar intrusion
- lower failure rate and negligible risk of mini-implant fracture as the anterior hard palate can be considered an optimum insertion site.

The duration treatment time for 2.3-4 mm intrusion of elongated upper molars with the Mousetrap appliance ranges from 4-10 months (unpublished data from our clinic, n=20). The average rate of molar intrusion of 0.33 mm/month compares favourably to conventional tooth borne molar intrusion as intrusion is initiated immediately, hence avoiding delays associated with customary levelling phase of 3-4 months of the anchorage teeth.

The Mousetrap molar intrusion mechanics may be used with or without a TPA. The placement of a TPA may reduce patient comfort but reduces the risk of tipping of the molars to be intruded. Conversely, the down-pared 'Mini-Mousetrap' appliance (without a TPA), must be closely monitored as molar movement progresses and the direction of the force may need to be adjusted in order to avoid unwanted tipping. The Mousetrap and Mini-Mousetrap are not only indicated for mere pre-prosthodontic intrusion of maxillary molars, but can be coupled with palatal TAD-borne sliders for intrusion and

simultaneous distalization<sup>31</sup> or for intrusion and mesialization<sup>32</sup> of teeth as part of an overall bio-mechanical plan.

## Conclusion

The choice of the anterior palate as a site of mini-implant placement minimizes the risk of failure or mini-implant fracture. Both Mousetrap and 'Mini-Mousetrap' have proven to be reliable devices for intrusion of supra-erupted molars.

## References

1. Kravitz ND, Kusnoto B, Tsay PT, Hohlt WF. Intrusion of overerupted upper first molar using two orthodontic miniscrews. *A case report. Angle Orthod.* 2007;77:915-922.
2. Kravitz ND, Kusnoto B, Tsay TP, Hohlt WF. The use of temporary anchorage devices for molar intrusion. *J Am Dent Assoc.* 2007;138:56-64.
3. Yao CC, Lee JJ, Chen HY, Chang ZC, Chang HF, Chen YJ. Maxillary molar intrusion with fixed appliances and mini-implant anchorage studied in three dimensions. *Angle Orthod.* 2005;75:754-760.
4. Sherwood KH, Burch JG, Thompson WJ. Closing anterior open bites by intruding molars with titanium miniplate anchorage. *Am J Orthod Dentofacial Orthop.* 2002;122:593-600.
5. Lin JC, Liou EJ, Yeh CL. Intrusion of overerupted maxillary molars with miniscrew anchorage. *J Clin Orthod.* 2006;40:378-383. quiz 358.
6. Wilmes B. Fields of Application of Mini-Implants. In: Ludwig B, Baumgaertel S, Bowman J, eds. *Innovative Anchorage Concepts. Mini-Implants in Orthodontics.* Berlin, New York: Quintessenz; 2008.
7. Erverdi N, Keles A, Nanda R. The use of skeletal anchorage in open bite treatment: a cephalometric evaluation. *Angle Orthod.* 2004;74:381-390.
8. Umemori M, Sugawara J, Mitani H, Nagasaka H, Kawamura H. Skeletal anchorage system for open-bite correction. *Am J Orthod Dentofacial Orthop.* 1999;115:166-174.
9. Moon CH, Wee JU, Lee HS. Intrusion of overerupted molars by corticotomy and orthodontic skeletal anchorage. *Angle Orthod.* 2007;77:1119-1125.
10. Cheng SJ, Tseng IY, Lee JJ, Kok SH. A prospective study of the risk factors associated with failure of mini-implants used for orthodontic anchorage. *Int J Oral Maxillofac Implants.* 2004;19:100-106.
11. Tsaousidis G, Bauss O. Influence of insertion site on the failure rates of orthodontic miniscrews. *J Orofac Orthop.* 2008;69:349-356.
12. Lee M, Shuman J. Maxillary molar intrusion with a single miniscrew and a transpalatal arch. *J Clin Orthod.* 2012;46:48-51.
13. Ludwig B, Glasl B, Kinzinger GS, Lietz T, Lisson JA. Anatomical guidelines for miniscrew insertion: Vestibular interradicular sites. *J Clin Orthod.* 2011;45:165-173.
14. Poggio PM, Incorvati C, Velo S, Carano A. "Safe zones": a guide for miniscrew positioning in the maxillary and mandibular arch. *Angle Orthod.* 2006;76:191-197.

15. Kim SH, Yoon HG, Choi YS, Hwang EH, Kook YA, Nelson G. Evaluation of interdental space of the maxillary posterior area for orthodontic mini-implants with cone-beam computed tomography. *Am J Orthod Dentofacial Orthop.* 2009;135:635–641.
16. Wilmes B, Panayotidis A, Drescher D. Fracture resistance of orthodontic mini-implants: a biomechanical in vitro study. *Eur J Orthod.* 2011;33:396–401.
17. Wiechmann D, Meyer U, Buchter A. Success rate of mini- and micro-implants used for orthodontic anchorage: a prospective clinical study. *Clin Oral Implants Res.* 2007;18:263–267.
18. Fritz U, Diedrich P. Clinical suitability of titanium micro-screws for orthodontic anchorage. In: Nanda R, Uribe FA, eds. *Temporary anchorage devices in orthodontics.* St. Louis: Mosby Elsevier; 2009:287–294.
19. Ludwig B, Glasl B, Bowman SJ, Wilmes B, Kinzinger GS, Lisson JA. Anatomical guidelines for miniscrew insertion: palatal sites. *J Clin Orthod.* 2011;45:433–441.
20. Miyawaki S, Koyama I, Inoue M, Mishima K, Sugahara T, Takano-Yamamoto T. Factors associated with the stability of titanium screws placed in the posterior region for orthodontic anchorage. *Am J Orthod Dentofacial Orthop.* 2003;124:373–378.
21. Chen YH, Chang HH, Chen YJ, Lee D, Chiang HH, Yao CC. Root contact during insertion of miniscrews for orthodontic anchorage increases the failure rate: an animal study. *Clin Oral Implants Res.* 2008;19:99–106.
22. Kadioglu O, Buyukyilmaz T, Zachrisson BU, Maino BG. Contact damage to root surfaces of premolars touching miniscrews during orthodontic treatment. *Am J Orthod Dentofacial Orthop.* 2008;134:353–360.
23. Maino BG, Weiland F, Attanasi A, Zachrisson BU, Buyukyilmaz T. Root damage and repair after contact with miniscrews. *J Clin Orthod.* 2007;41:762–766. quiz 750.
24. Gracco A, Tracey S, Baciliero U. Miniscrew insertion and the maxillary sinus: an endoscopic evaluation. *J Clin Orthod.* 2010;44:439–443.
25. Karagkiolidou A, Ludwig B, Pazera P, Gkantidis N, Pandis N, Katsaros C. Survival of palatal miniscrews used for orthodontic appliance anchorage: A retrospective cohort study. *Am J Orthod Dentofacial Orthop.* 2013;143:767–772.
26. Wilmes B, Nienkemper M, Ludwig B, Nanda R, Drescher D. Upper-molar intrusion using anterior palatal anchorage and the Mousetrap appliance. *J Clin Orthod.* 2013;47:314–320.
27. Wilmes B, Vasudavan S, Stocker B, Willmann JH, Drescher D. Closure of an open bite using the 'Mousetrap' appliance: a 3-year follow-up. *Aust Orthod J.* 2015;31:208–215.
28. Wilmes B, Ludwig B, Vasudavan S, Nienkemper M, Drescher D. The T-Zone: Median vs. Paramedian Insertion of Palatal Mini-Implants. *J Clin Orthod.* 2016;50:543–551.
29. Becker K, Unland J, Wilmes B, Tarraf NE, Drescher D. Is there an ideal insertion angle and position for orthodontic mini-implants in the anterior palate? A CBCT study in humans. *Am J Orthod Dentofacial Orthop.* 2019;156:345–354.
30. Wilmes B, Drescher D, Nienkemper M. A miniplate system for improved stability of skeletal anchorage. *J Clin Orthod.* 2009;43:494–501.
31. Wilmes B, Neuschulz J, Safar M, Braumann B, Drescher D. Protocols for combining the Beneslider with lingual appliances in Class II treatment. *J Clin Orthod.* 2014;48:744–752.
32. Wilmes B, Katyal V, Willmann J, Stocker B, Drescher D. Mini-implant-anchored Mesialslider for simultaneous mesialisation and intrusion of upper molars in an anterior open bite case: a three-year follow-up. *Aust Orthod J.* 2015;31:87–97.