

OVERVIEW

The T-Zone: Median vs. Paramedian Insertion of Palatal Mini-Implants

BENEDICT WILMES, DMD, MSD, PhD
BJÖRN LUDWIG, DMD, MSD
SIVABALAN VASUDAVAN, BDS_c, MDS_c, MPH
MANUEL NIENKEMPER, DMD, PhD
DIETER DRESCHER, DMD, PhD

(Editor's Note: In this regular column, JCO provides an overview of a clinical topic of interest to orthodontists. Contributions and suggestions for future subjects are welcome.)

Mini-implants have become a commonly used adjunctive orthodontic treatment modality because of their biomechanical versatility, minimal invasiveness, and relative cost-effectiveness. Innovative solutions have been developed for a variety of treatment objectives, including molar distalization^{1,2} and mesialization,³ molar intrusion,⁴

extrusion of impacted teeth,⁵ midline correction,⁶ early Class III treatment,⁷ and anterior and buccal anchorage.⁸

Although the preferred insertion site for mini-implants is the alveolar process,⁹⁻¹³ this location still shows an average failure rate of 16.1% due to varying bone and soft-tissue conditions.¹⁴⁻¹⁷ Five strategies have been proposed to enhance the prospects of successful mini-implant retention:

1. Select the optimal insertion site.
2. Avoid direct root contact with the implant.
3. Avoid placing an implant within the intended path of tooth movement.



Dr. Wilmes



Dr. Ludwig



Dr. Vasudavan



Dr. Nienkemper



Dr. Drescher

Dr. Wilmes is a Professor, Department of Orthodontics, University of Düsseldorf, Moorenstrasse 5, 40225 Düsseldorf, Germany; a Visiting Professor, Department of Orthodontics, University of Alabama at Birmingham School of Dentistry; and the developer of the Benefit System; e-mail: wilmes@med.uni-duesseldorf.de. Dr. Vasudavan is an adjunct faculty member, Department of Dentistry, Boston Children's Hospital, and a Visiting Lecturer, Department of Developmental Biology, Harvard School of Dental Medicine, Boston. Dr. Ludwig is a Contributing Editor of the *Journal of Clinical Orthodontics*; an Instructor, Department of Orthodontics, University of Homburg, Saar, Germany; and in the private practice of orthodontics in Traben-Trarbach, Germany. Dr. Nienkemper is a Visiting Lecturer, Department of Orthodontics, University of Düsseldorf, and in the private practice of orthodontics in Düsseldorf. Dr. Drescher is a Professor and Head, Department of Orthodontics, University of Düsseldorf.

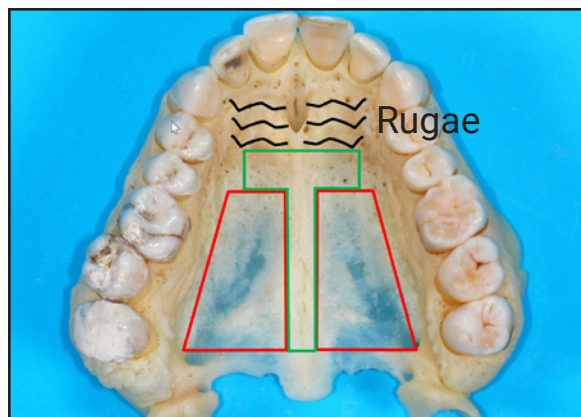


Fig. 1 Recommended insertion site posterior to palatal rugae (“T-Zone”). Bone is too thin in posterior and lateral areas.

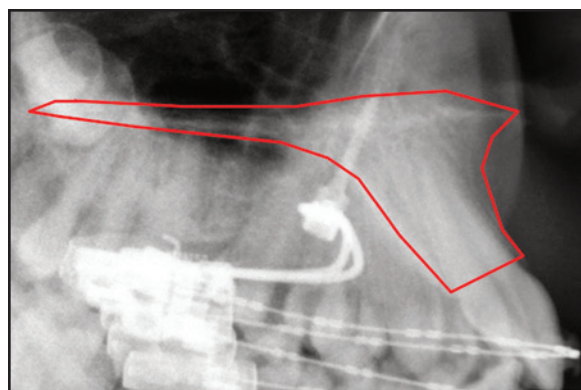


Fig. 2 Median insertion of single mini-implant.

4. Use tandem implants to prevent tipping and rotational tendencies secondary to the development of couples.
5. Use implants that have sufficient length and diameter.

The anterior palate is a good alternative insertion site because it allows mini-implants with larger dimensions and greater stability^{1,18} to be placed in a region with high bone quality, thin overlying soft tissue, and a nearly negligible risk of root damage or interference with teeth.¹⁹ Insertion in the anterior palate rather than the alveolar ridge, combined with the previously listed strate-

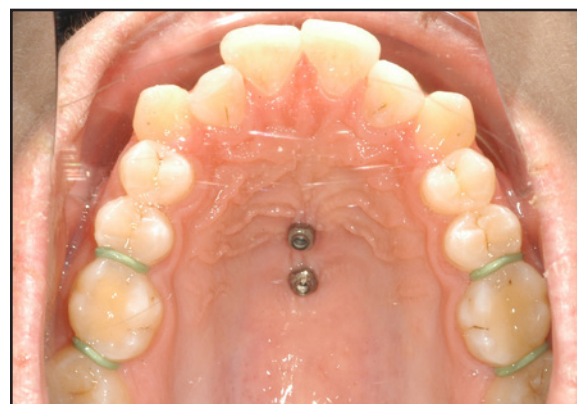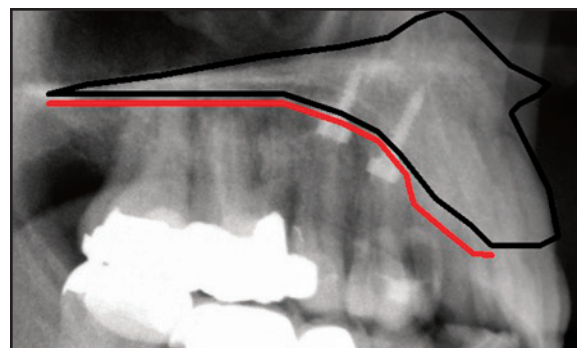


Fig. 3 For median insertion, pair of mini-implants should be 7-14mm apart (red line represents soft-tissue layer, which is thicker anteriorly).

gies, can reduce the mini-implant failure rate to as low as 2.1%.²⁰

Mini-Implant Insertion Sites

The clinician should easily be able to identify the optimal insertion site within the maxilla. Available bone volume, soft-tissue thickness, and proximity to structures such as blood vessels, roots, and nerves must be assessed. Because the bone volume is reduced in the lateral and posterior areas of the palate,^{19,21} only a median insertion is possible in the posterior palate. Near the incisors, the palate is covered with the thick soft tissue of the palatal rugae, which is associated with an increased risk of tipping and failure.²² Additionally, the proximity of such structures as the incisor roots and the incisive canals must be considered.

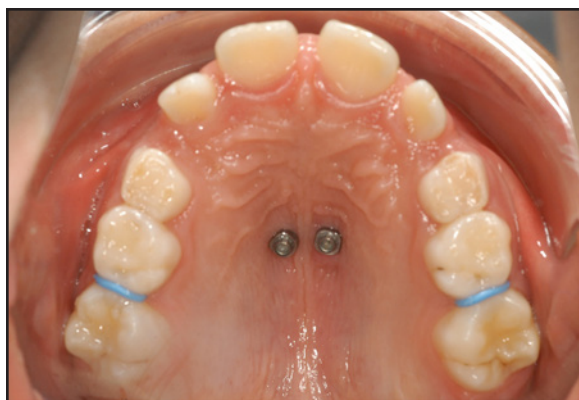
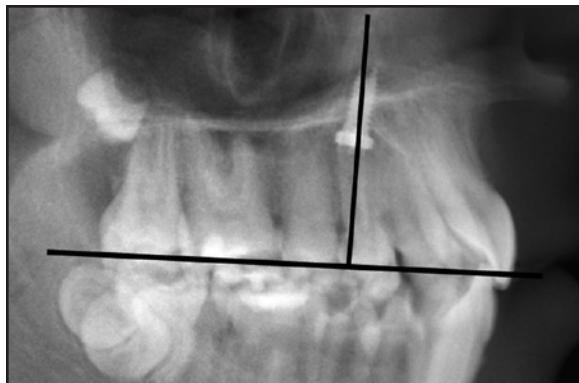
Fig. 4 For paramedian insertion, pair of mini-implants should be placed perpendicular to occlusal plane to minimize risk of incisor root damage.

Therefore, insertion of a mini-implant directly within the palatal rugae can be challenging.

The area immediately posterior to the palatal rugae, referred to here as the “T-Zone”, is a more suitable region for insertion of palatal mini-implants due to the available bone volume (Fig. 1). In a case with symmetrical anchorage requirements, a single mini-implant of adequate length and diameter (for example, 2.3mm × 9mm) may be sufficient (Fig. 2). When rotational torquing forces are applied, two mini-implants may need to be coupled to reduce the risk of tipping and potential failure. Two adjacent mini-implants can be positioned in a sagittal direction (median insertion) or a transverse direction (paramedian insertion).²³ If a median pattern of insertion is indicated, the implants are placed along an anteroposterior line

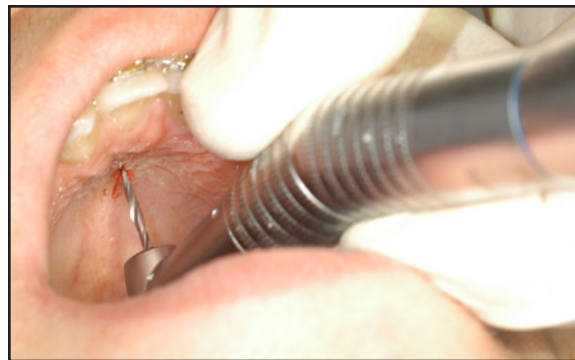

Fig. 5 Predrilling in adult patient.

within the T-Zone, 7-14mm apart (Fig. 3). For a paramedian insertion, the mini-implants are placed in a transverse configuration; in this case, the presence of thick lateral soft tissue limits the distance between the mini-implants to 5-10mm (Fig. 4).

Mini-Implant Insertion

Insertion of mini-implants typically begins with two paramedian depots of a local anesthetic. The Citoject* is our preferred method of delivery because of its minuscule needle size. If the patient or orthodontist has concerns regarding the use of a needle, the mini-implant may be inserted under a topical anesthetic. In an adult patient, who will usually have areas of high bone density in the anterior hard palate, a pilot hole should be drilled to a depth of 2-3mm (Fig. 5).²⁴ Predrilling is not required in children and young adolescents because of their low bone mineralization.²⁵

A diameter of 2mm or 2.3mm and length of 9mm (anteriorly) and 7mm (posteriorly) will ensure stability of the implant.²⁴⁻²⁷ The implants can be inserted manually (Fig. 6) or with a motorized implant driver (Fig. 7). Specific differences regarding paramedian vs. median insertion should be considered when determining the placement pattern (Table 1).

To achieve maximal retention within bone, the tip of a median-inserted implant should be

*Sopira, registered trademark of Heraeus Kulzer, South Bend, IN; www.heraeus-kulzer-us.com.

**TABLE 1
FACTORS TO CONSIDER WITH MEDIAN VS.
PARAMEDIAN MINI-IMPLANT INSERTION**

	Median	Paramedian
Angulation	Perpendicular to the bone	Perpendicular to the occlusal plane
Mini-implant length	Anterior: 9-11mm; posterior: 7-9mm	7-9mm

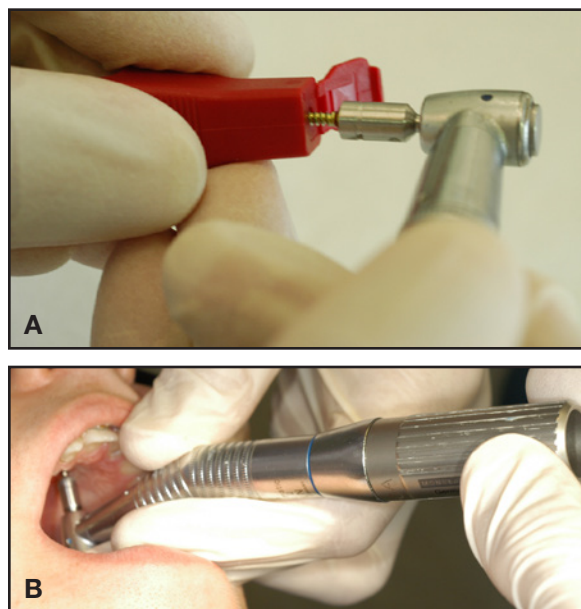


Fig. 6 A. Retrieval of mini-implant from package, without touching surface of screw. B. Mini-implant insertion using contra-angle and hand-piece.

perpendicular to the palatal vault (approximately 10-30° perpendicular to the occlusal plane) during insertion. Given the abundant quantity of available bone within the region of the anterior hard palate, a longer, 9-11mm mini-implant can be utilized.¹⁹

To reduce the potential risk of incisor root contact and concomitant damage, a paramedian mini-implant should not be angled anteriorly, but should be inserted directly perpendicular to the occlusal plane. Given the relatively lower volume of bone within this region, a shorter, 7-9mm mini-implant is indicated.

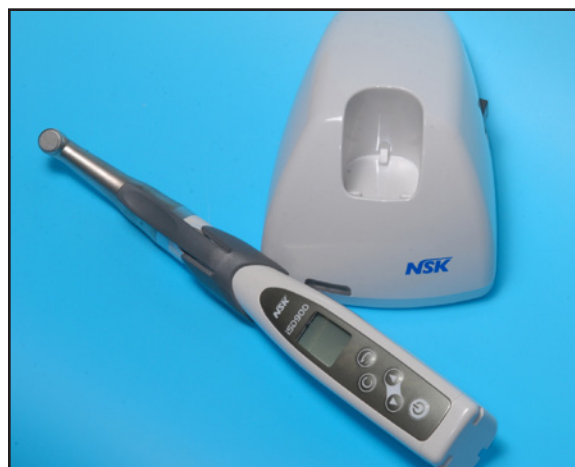

Fig. 7 Motorized driver used for mini-implant insertion.**

Appliance Construction

When placing a single mini-implant, various abutments can be applied with a small fixation screw on top of the screw head (Fig. 8). To avoid the need for a laboratory procedure, an abutment with a prefabricated .032" or .045" wire can be selected.

In cases with higher anchorage demands, two mini-implants can be coupled using a Beneplate,^{***} which is available in two different lengths (Fig. 9).²³ For easy connection to an orthodontic appliance without lab work, a Beneplate with an attached .032" or .045" stainless steel wire is rec-

**NSK, Hoffman Estates, IL; www.nsk-dental.com.

***PSM Medical Solutions, Tuttingen, Germany; www.psm.ms. Distributed in the U.S. by PSM North America, Indio, CA; www.psm-na.us.




Fig. 8 Benefit System*** components. A. Mini-implant. B. Abutment with attached .032" or .045" wire. C. Abutment with bracket. D. Standard abutment. E. Abutment with slot. F. Screwdriver.

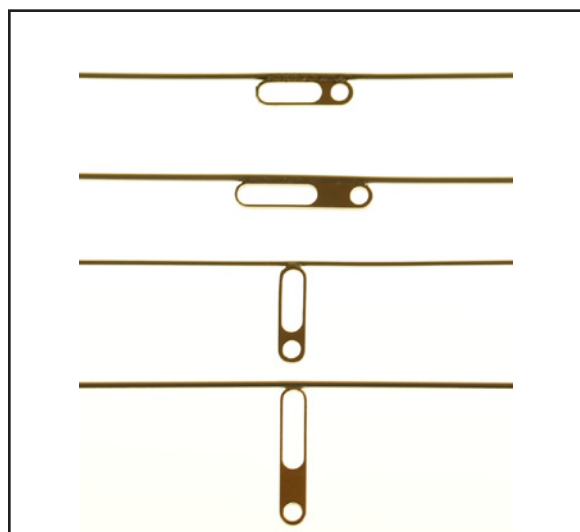


Fig. 9 Short and long Beneplates*** with attached wires parallel and perpendicular to Beneplate body.

ommended. The Beneplate can be adapted to two or even three palatal mini-implants by adjusting the miniplate body and wire (Fig. 10). In many cases, this adaptation can be made directly in the mouth. Alternatively, an intraoral impression can be used (Fig. 11), and the clinical setup transferred to a plaster cast using an impression cap and laboratory analog from the Benefit System.***²⁸

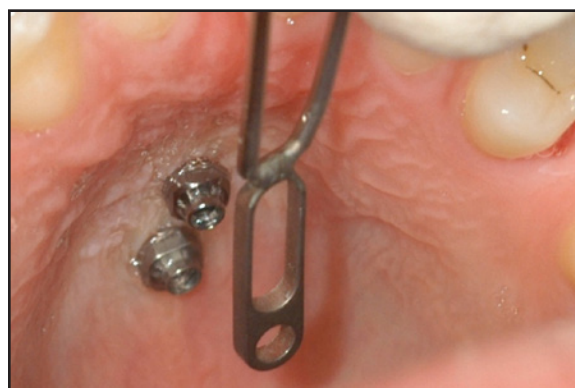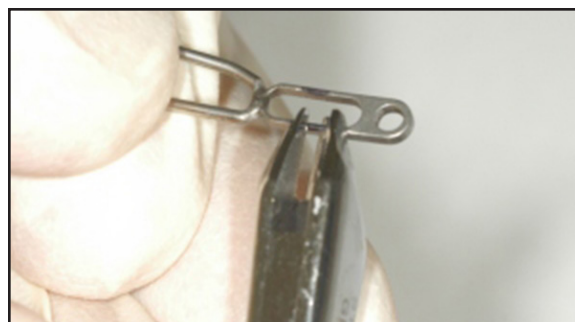


Fig. 10 Intraoral adaptation of Beneplate without lab work.

Distalizing Appliance Design

The Beneslider*** is a distalization appliance anchored by one or two mini-implants in the anterior palate, using an .045" stainless steel wire for the sliding mechanism.^{1,13,23,28} If a single mini-implant is used, an abutment with an attached wire is affixed for the application of distalization mechanics. To improve stability, two mini-implants can be coupled with a Beneplate.²³ The Benetubes*** of the distalization appliance are engaged in the conventional palatal sheaths of the upper-molar bands.

The Beneslider system does not require adjunctive soldering or welding; it can be adapted directly at the chair without an impression or laboratory procedure. If the mini-implants are inserted in a median pattern, a Beneplate with a wire perpendicular to the body is indicated; for paramedian insertion, a parallel wire should be used (Table 2). The extension wire can be angulated to achieve either simultaneous intrusion of the upper molars

**TABLE 2
BENESLIDER DESIGN WITH MEDIAN VS.
PARAMEDIAN MINI-IMPLANT INSERTION**

	Median	Paramedian
Supraconstruction using two temporary anchorage devices	Two abutments, or Beneplate with wire perpendicular to the Beneplate body	Two abutments, or Beneplate with wire parallel to the Beneplate body

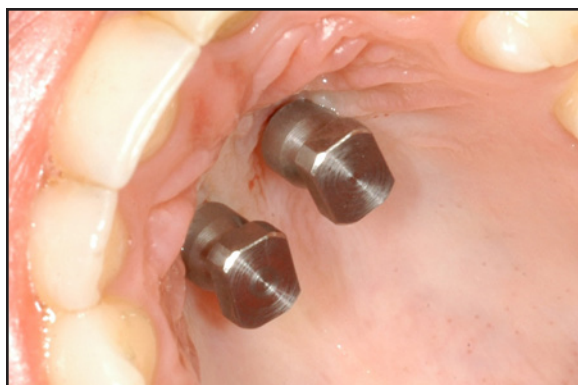
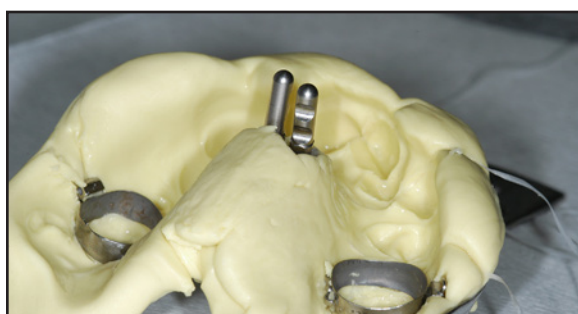

Fig. 11 To reduce chairtime, impression can be used to design mechanics on plaster cast (impression is required for Hybrid Hyrax†).

(for an open bite) or simultaneous extrusion (for a deep bite).¹⁸ The distalization force is delivered by compressible springs of either 240g or 500g, which are activated by bilateral locking mechanisms that push the Benetubes distally. Follow-up appointments should be scheduled every four to six weeks.

The premolars and canines normally follow the molars and migrate distally, due to the pull of the interdental collagenous fibers. After molar

distalization has been completed, the remaining treatment objectives can be achieved through the use of labial or lingual fixed appliances or clear aligners. The springs are removed from the Beneslider, converting it to a passive device for molar anchorage during anterior retraction.

Case 1

A 13-year-old male patient presented with upper crowding and incisor protrusion (Fig. 12A). Distalization was performed using a Beneslider appliance and two mini-implants with median insertion (Fig. 12B). After seven months, leveling and alignment were initiated with fixed appliances‡ and an .016" SPEED Supercable†† nickel titanium archwire (Fig. 12C). Total treatment time was 13 months. The results remained stable one year after completion of treatment (Fig. 12D).

Case 2

A 9-year-old female patient presented with a lack of space for her upper canines. After a pair of mini-implants was placed in a paramedian pattern (Fig. 13A), a Beneslider was used for distalization (Fig. 13B). After nine months, enough space had been created to begin leveling and alignment (Fig. 13C). Total treatment time was two

***PSM Medical Solutions, Tuttlingen, Germany; www.psm.ms. Distributed in the U.S. by PSM North America, Indio, CA; www.psm-na.us.

†Trademark of Dentaurum, Inc., Newtown, PA; www.dentaurum.com.

‡Ormco Corporation, Orange, CA; www.ormco.com.

††Strite Industries Ltd., Cambridge, ON; www.speedsystem.com.

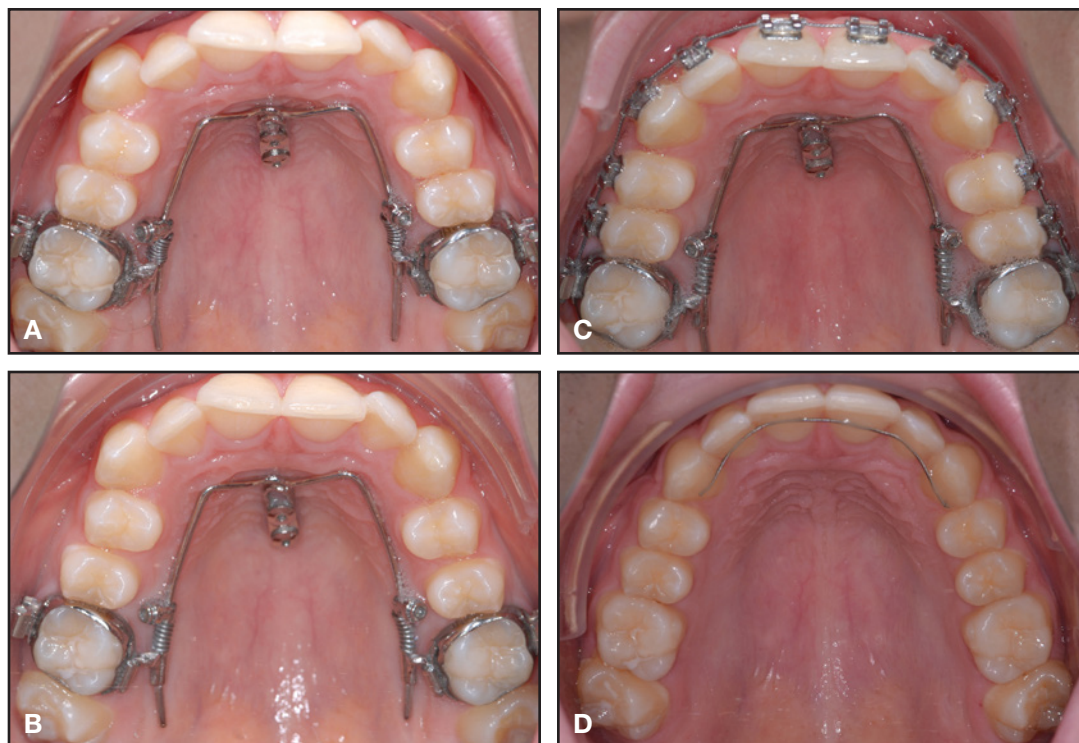


Fig. 12 Case 1. A. 13-year-old male patient with upper crowding and incisor protrusion. B. Generalized spacing after four months of distalization using Beneslider*** appliance and mini-implants with median insertion. C. Initiation of leveling and alignment with fixed appliances‡ and .016" SPEED Supercable†† nickel titanium archwire after seven months of treatment. D. Patient after one year of retention.

years. Results remained stable after six months of retention (Fig. 13D).

Discussion

The choice between a median and paramedian pattern of palatal mini-implant insertion depends mainly on the biomechanical plan devised for each patient. There is no difference between the two patterns regarding retention and stability of the mini-implants, even in children and adolescents.^{29,30}

The potential inhibition of transverse maxillary growth by dental implants placed in the median region of the midpalatal suture was investigated in dogs by Asscherickx and colleagues.³¹ In this study, however, only one control animal was available, and a significant difference was found for only one parameter.³² Moreover, the applicabil-

ity of the findings to mini-implants is questionable due to the greater diameter and surface roughness of dental implants. In our institution, we have not seen any tendency for median-inserted mini-implants to impede transverse maxillary growth.

In fact, a median insertion may be advantageous due to the reduced risk of injury to the upper-incisor roots (Table 3). A secondary advantage of median insertion is that the mini-implants can be placed more anteriorly, where the maximum distance through the maxillary bone is available. On the other hand, penetration of the incisive canals is more likely than with paramedian insertion. We have never observed a case of persistent anesthesia, even when penetration of the incisive canals was detected with three-dimensional imaging, but such penetration may result in reduced bony anchorage and thus contribute to a higher mini-implant failure

**TABLE 3
PROS AND CONS OF MEDIAN VS. PARAMEDIAN MINI-IMPLANT INSERTION**

	Median	Paramedian
Insertion with an anterior angulation possible (more available bone)?	Yes	No
Coupling in the line of force (sagittal tooth movements)?	Yes	No
Risk of root damage?	Very low	Yes
Possible penetration of the incisive canals?	Yes	No
Possible interference with the suture?	Yes	No

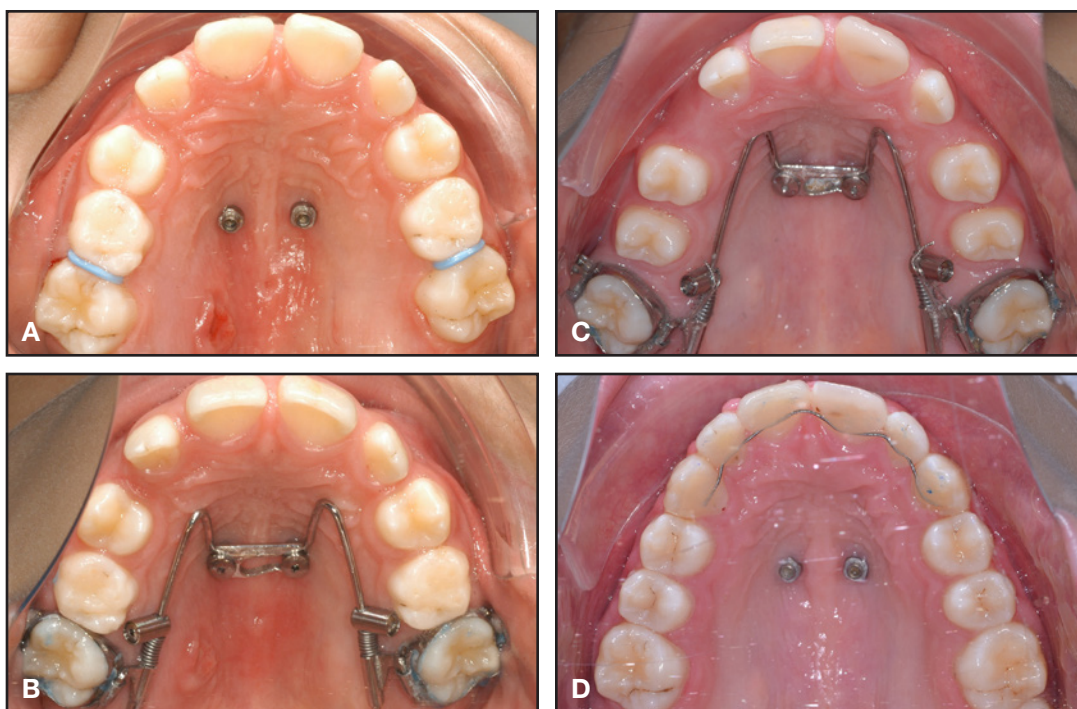


Fig. 13 Case 2. A. Mini-implants with paramedian insertion in 9-year-old female patient with lack of space for upper canines. B. Beneslider appliance placed for distalization. C. After nine months of distalization, sufficient space created for leveling and alignment. D. Patient after six months of retention.

rate. As a general rule, mini-implants should not be inserted directly into the anterior area of the palatal rugae, but posterior to the third palatal rugae within the T-Zone.

Conclusion

The anterior palate is an ideal site for predict-

able and reliable placement of mini-implants. Within the demarcations of the T-Zone, the orthodontist has a choice of positioning mini-implants in either a median or a paramedian pattern. While carefully considering the anatomical features of the insertion site, the clinician must determine the biomechanics needed to achieve treatment goals and then adapt the selected location for specific

appliance design. Median insertion is appropriate for sagittal and vertical tooth movements and for maxillary expansion in patients with palatally impacted upper canines. Paramedian insertion is preferable for rapid maxillary expansion and subsequent sagittal and vertical tooth movements.

REFERENCES

1. Wilmes, B. and Drescher, D.: Application and effectiveness of the Beneslider: A device to move molars distally, *World J. Orthod.* 11:331-340, 2010.
2. Nienkemper, M.; Wilmes, B.; Pauls, A.; Yamaguchi, S.; Ludwig, B.; and Drescher, D.: Treatment efficiency of mini-implant-borne distalization depending on age and second-molar eruption, *J. Orofac. Orthop.* 75:118-132, 2014.
3. Wilmes, B.; Nienkemper, M.; Nanda, R.; Lübberink, G.; and Drescher, D.: Palatally anchored maxillary molar mesialization using the mesialslider, *J. Clin. Orthod.* 47:172-179, 2013.
4. Wilmes, B.; Nienkemper, M.; Ludwig, B.; Nanda, R.; and Drescher, D.: Upper-molar intrusion using anterior palatal anchorage and the Mousetrap appliance, *J. Clin. Orthod.* 47:314-320, 2013.
5. Wilmes, B. and Drescher, D.: Vertical periodontal ligament distraction—A new method for aligning ankylosed and displaced canines, *J. Orofac. Orthop.* 70:213-223, 2009.
6. Wilmes, B.; Nanda, R.; Nienkemper, M.; Ludwig, B.; and Drescher, D.: Correction of upper-arch asymmetries using the Mesial-Distalslider, *J. Clin. Orthod.* 47:648-655, 2013.
7. Wilmes, B.; Nienkemper, M.; Ludwig, B.; Kau, C.H.; and Drescher, D.: Early Class III treatment with a Hybrid Hyrax-Mentoplate combination, *J. Clin. Orthod.* 45:15-21, 2011.
8. Wilmes, B.; Olthoff, G.; and Drescher, D.: Comparison of skeletal and conventional anchorage methods in conjunction with pre-operative decompensation of a skeletal Class III malocclusion, *J. Orofac. Orthop.* 70:297-305, 2009.
9. Costa, A.; Raffaini, M.; and Melsen, B.: Miniscrews as orthodontic anchorage: A preliminary report, *Int. J. Adult Orthod. Orthog. Surg.* 13:201-209, 1998.
10. Freudenthaler, J.W.; Haas, R.; and Bantleon, H.P.: Bicortical titanium screws for critical orthodontic anchorage in the mandible: A preliminary report on clinical applications, *Clin. Oral Implants Res.* 12:358-363, 2001.
11. Kanomi, R.: Mini-implant for orthodontic anchorage, *J. Clin. Orthod.* 31:763-767, 1997.
12. Melsen, B. and Costa, A.: Immediate loading of implants used for orthodontic anchorage, *Clin. Orthod. Res.* 3:23-28, 2000.
13. Wilmes, B.: Fields of application of mini-implants, in *Mini-Implants in Orthodontics: Innovative Anchorage Concepts*, ed. B. Ludwig, S. Baumgaertel, and S.J. Bowman, Quintessenz, Berlin, 2008.
14. Berens, A.; Wiechmann, D.; and Dempf, R.: Mini- and micro-screws for temporary skeletal anchorage in orthodontic therapy, *J. Orofac. Orthop.* 67:450-458, 2006.
15. Cheng, S.J.; Tseng, I.Y.; Lee, J.J.; and Kok, S.H.: A prospective study of the risk factors associated with failure of mini-implants used for orthodontic anchorage, *Int. J. Oral. Maxillofac. Implants* 19:100-106, 2004.
16. Fritz, U.; Ehmer, A.; and Diedrich, P.: Clinical suitability of titanium microscrews for orthodontic anchorage—preliminary experiences, *J. Orofac. Orthop.* 65:410-418, 2004.
17. Miyawaki, S.; Koyama, I.; Inoue, M.; Mishima, K.; Sugahara, T.; and Takano-Yamamoto, T.: Factors associated with the stability of titanium screws placed in the posterior region for orthodontic anchorage, *Am. J. Orthod.* 124:373-378, 2003.
18. Wilmes, B.; Neuschulz, J.; Safar, M.; Braumann, B.; and Drescher, D.: Protocols for combining the Beneslider with lingual appliances in Class II treatment, *J. Clin. Orthod.* 48:744-752, 2014.
19. Kang, S.; Lee, S.J.; Ahn, S.J.; Heo, M.S.; and Kim, T.W.: Bone thickness of the palate for orthodontic mini-implant anchorage in adults, *Am. J. Orthod.* 131:S74-S81, 2007.
20. Karagiolidou, A.; Ludwig, B.; Pazera, P.; Gkantidis, N.; Pandis, N.; and Katsaros, C.: Survival of palatal miniscrews used for orthodontic appliance anchorage: A retrospective cohort study, *Am. J. Orthod.* 143:767-772, 2013.
21. Hourfar, J.; Kanavakis, G.; Bister, D.; Schatzle, M.; Awad, L.; Nienkemper, M.; Goldbecher, C.; and Ludwig, B.: Three dimensional anatomical exploration of the anterior hard palate at the level of the third ruga for the placement of mini-implants—A cone-beam CT study, *Eur. J. Orthod.* 37:589-595, 2015.
22. Büchter, A.; Wiechmann, D.; Koerdt, S.; Wiesmann, H.P.; Piffko, J.; and Meyer, U.: Load-related implant reaction of mini-implants used for orthodontic anchorage, *Clin. Oral Implants Res.* 16:473-479, 2005.
23. Wilmes, B.; Drescher, D.; and Nienkemper, M.: A miniplate system for improved stability of skeletal anchorage, *J. Clin. Orthod.* 43:494-501, 2009.
24. Wilmes, B.; Rademacher, C.; Olthoff, G.; and Drescher, D.: Parameters affecting primary stability of orthodontic mini-implants, *J. Orofac. Orthop.* 67:162-174, 2006.
25. Wilmes, B.; Su, Y.Y.; and Drescher, D.: Insertion angle impact on primary stability of orthodontic mini-implants, *Angle Orthod.* 78:1065-1070, 2008.
26. Wilmes, B.; Ottenstreuer, S.; Su, Y.Y.; and Drescher, D.: Impact of implant design on primary stability of orthodontic mini-implants, *J. Orofac. Orthop.* 69:42-50, 2008.
27. Wilmes, B.; Su, Y.Y.; Sadigh, L.; and Drescher, D.: Pre-drilling force and insertion torques during orthodontic mini-implant insertion in relation to root contact, *J. Orofac. Orthop.* 69:51-58, 2008.
28. Wilmes, B. and Drescher, D.: A miniscrew system with interchangeable abutments, *J. Clin. Orthod.* 42:574-580, 2008.
29. Nienkemper, M.; Pauls, A.; Ludwig, B.; and Drescher, D.: Stability of paramedian inserted palatal mini-implants at the initial healing period: A controlled clinical study, *Clin. Oral Implants Res.* 26:870-875, 2015.
30. Nienkemper, M.; Wilmes, B.; Pauls, A.; and Drescher, D.: Mini-implant stability at the initial healing period: A clinical pilot study, *Angle Orthod.* 84:127-133, 2014.
31. Asscherickx, K.; Hanssens, J.L.; Wehrbein, H.; and Sabzevar, M.M.: Orthodontic anchorage implants inserted in the median palatal suture and normal transverse maxillary growth in growing dogs: A biometric and radiographic study, *Angle Orthod.* 75:826-831, 2005.
32. Borsos, G.; Rudzki-Janson, I.; Stockmann, P.; Schlegel, K.A.; and Végh, A.: Immediate loading of palatal implants in still-growing patients: A prospective, comparative, clinical pilot study, *J. Orofac. Orthop.* 69:297-308, 2008.