

# CLINICAL REVIEW

Orthodontic



**Rapid Maxillary  
Expansion**  
with Skeletal Anchorage

**QUAD HELIX  
INNOVATIONS**

**CLASS II**  
Corrections Using  
Sectional Mechanics

**DR. RICKETTS**  
TRIBUTE

**CONTEMPORARY  
BIOPROGRESSIVE  
THERAPY**

Controlling the  
Vertical Dimension

## Remembering Dr. Ricketts

The last time I saw Dr. Ricketts was in Maui, Hawaii 2003 during the F.O.R. (Foundation for Orthodontic Research) annual meeting following the AAO in Waikiki. The last time I spoke with him was while he was on the massage table getting ready to have dinner with his family—later that night he had complications and passed away the next morning.

Dr. Ricketts dedicated his life to the advancement of orthodontics and it was a topic that he was always eager to discuss. Since the very beginning, Dr. Ricketts realized that it would be a long, tough battle to bring about change to long held beliefs concerning orthodontics. In 1973 he wrote the “Doctrine of Limitations.” To this day, the fundamental concepts of this article hold true.

Dr. Ricketts was an innovator whose thinking was often generations ahead of the profession. RMO’s founder Dr. Archie Brusse realized this back in 1955.

In 1959 Archie instructed his son, Martin Brusse, to stay close to Dr. Ricketts. Archie said “I don’t understand Dr. Ricketts, but I know that he has a vision to be realized.” Archie also emphasized that Dr. Ricketts was an inspired and strong person and RMO should work with him to help make his vision a reality.

Now, as we fast forward to 2012, RMO and the entire orthodontic community continues to benefit from the original partnership that was established with Dr. Ricketts.

I came to know Dr. Ricketts in the early 90’s when Martin Brusse decided to send me to attend a lecture at the Bioprogressive Institute in Scottsdale, Arizona entitled “The Bioprogressive Philosophy Series of Courses (6).”

The journey was an unforgettable learning experience and started a long friendship with Dr. Ricketts. He was a great teacher, innovator, father, friend, and thinker. He always had the benefits of others in mind especially the patients.

He taught me to always think of the patients first and their overall health and



to never stop learning “keep your mind stimulated...” Ricketts also taught us that there is one certainty in life other than death; it is that change is inevitable, and we must adapt to the change.

Dr. Ricketts collaborated with Dr. Ruel Bench and Dr. Carl Gugino, to develop the Bioprogressive philosophy. This philosophy incorporated a biological approach to diagnosis and treatment options, and always looked at the patient as a whole – not just straightening the teeth. In 1981 Dr. Rick Jacobson joined Dr. Rickett’s practice and even now continues to incorporate the basic Bioprogressive principles that Dr. Ricketts developed.

Over the years, I spent a lot of time with Dr. Ricketts, including many long flights. Dr. Ricketts seemed like he never rested, not even on these flights. He was always thinking, writing, and considering new concepts. Some of the ideas that he came up with that RMO incorporated include:

- Computer Aided Orthodontic Diagnosis**
- Lateral and Frontal Analysis
  - Long Term Visual Treatment Objective (VTO)
  - Growth prediction to maturity

**Adding the dimension of time to treatment parameters (4D)**

**Appliance differentiation based on facial type – built into brackets and tubes**

- Mesofacial
- Brachyfacial
- Dolicofacial

He also published books and articles to support the evolution and improvement of the Bioprogressive philosophy.

Dr. Ricketts also had other product related ideas such as:

- Self Ligating brackets (from the 1970s)
- The Snap Channel concept
- Ribbon type arch wires
- Tooth colored bicuspid bands for lingual retainers

RMO is very proud to have worked with Dr. Ricketts and to have helped assure that his vision became a reality. RMO will continue to work with the co-founders of the Bioprogressive philosophy and the many clinicians around the world who are dedicated to the same teachings and philosophy.

“On behalf of all the RMO® people worldwide, we will never forget you; you will always be in our hearts and on our minds. This Clinical Review is dedicated to you.”

Tony Zakhem, Chairman and CEO



## TABLE OF CONTENTS

### 2 Remembering DR. RICKETTS

Tony Zakhem, CEO

### 5 CONTRIBUTORS

Doctor Profiles

### 6 Perspective in Bioprogressive Therapy

Ruel W. Bench, DDS

### 8 Contemporary BIOPROGRESSIVE Therapy

Nelson Oppermann, DDS, MS

### Rapid Maxillary Expansion 18 with Skeletal Anchorage Vs. Bonded Tooth/Tissue Born Expanders:

A case report comparison utilizing CBCT

Robert L. Vanarsdall, Jr. DDS

### 24 Control of Vertical Dimension During Sagittal Orthopedic Correction: The Death of the Wedge Effect Theory and the Birth of the Decompression Theory

Sergio Sambataro, DDS, MS, PhD


### 37 Class II Correction with Sectional Mechanics/Distalization Revisited

Enrique García Romero, DDS

### 44 Quad Helix Innovations: Pocket Aces

Duane Grummons, DDS, MSD

### 51 Tribute to DR. RICKETTS



# Become our **FAN** on **FACEBOOK**

to receive educational information  
and monthly promotions



 become a **FAN** of RMO®'s  
facebook page!  
[www.facebook.com/rmortho](http://www.facebook.com/rmortho)

**RMO**®  
rocky mountain orthodontics

### Ruel W. Bench, DDS

Dr. Bench was associated with Dr. Robert M. Ricketts in the practice and teaching of orthodontics. They developed and taught Bioprogressive therapy and treatment philosophy and the computerized cephalometric diagnostics. He served a three year preceptorship under Dr. Ricketts in conjunction with UCLA and the American Association of Orthodontics from 1959 to 1962. His thesis, "The Growth of the Cervical Vertebrae and Related to Tongue Poster", was awarded a Milo Helman Research Award. He has lectured and given courses in North America, South America, Europe, Africa, Asia and Australia. Along with Rocky Mountain Orthodontics, he developed a mini edgewise orthodontic bracket system using metal injection molding in addition to preformed arch wires for Bioprogressive therapy. Dr. Bench is currently an Associate Professor at Loma Linda.

### Nelson Oppermann, DDS, MS

Nelson Oppermann received his Masters degree in orthodontics in 2003 from SL Mandic Dental Research School in Campinas, Brazil. He worked as an associate professor at the Associação dos Cirurgiões-Dentistas de Campinas and SL Mandic Dental Research School, Brazil. Dr. Oppermann is a guest lecturer at the University of Illinois and has lectured around the world on many orthodontic topics. Dr. Oppermann specializes in presenting Bioprogressive ideas and clinical cases both didactically and clinically. He is a member of the AAO and the WFO.

### Robert L. Vanarsdall, Jr. DDS

Dr. Robert Vanarsdall is Professor of Orthodontics and Director of the Division of Advanced Dental Education at the University of Pennsylvania, School of Dental Medicine where he has been teaching full-time for over 40 years. He received his dental degree from the Medical College of Virginia and completed his post-doctoral specialty training at the University of Pennsylvania and is board certified in both Orthodontics and Periodontics. In addition to his teaching commitment, he maintains a private practice. For 17 years he served as Editor-in-Chief for the International Journal of Adult Orthodontics and Orthognathic Surgery in addition to other editorial board commitments; he co-authored with Dr. Tom Graber the text Orthodontics:

Current Principles and Techniques, 3rd 4th and 5th editions as well as Applications of Orthodontic Mini Implants, with JS Lee, JK Kim, Y-C Park, Quintessence Publishing, 2007.

### Ignacio Blasi Jr., DDS

Dr. Ignacio Blasi Jr. completed his dental training at the Universitat de Catalunya (UIC) at Barcelona (Spain) in 2007. After 2 years of private practice, he started his orthodontic training in 2009 at the Orthodontic Department at the University of Pennsylvania. He received the Colgate National Award in dental research, has presented at various meetings and published on the effects of different types of palatal expanders. His topics of interest are perio-ortho, esthetics, multidisciplinary treatment, occlusion, TMD and airways.

### Marianna Evans, DMD

Dr. Marianna Evans is a full-time practicing orthodontist, periodontist and dental implant surgeon. She is a diplomate of the American Board of Periodontology and eligible for the American Board of Orthodontics. Her interdisciplinary training and years of clinical experience allow her to see the interconnectivity of gum disease, malocclusion and skeletal function in a way few specialists can. Dr. Evans is a Clinical Associate at the University of Pennsylvania Department of Orthodontics and developed several orthopedic and plastic surgical techniques within her specialties. She frequently lectures on orthodontics, periodontics and dental implants both within the United States and around the world.

### Paul Kocian, DDS

Attended dental school at the University of Minnesota School of Dentistry. After graduation in 2006, he completed a 1-year AEGD residency and 2 years general practice while serving in the U.S. Navy. His postgraduate orthodontic training began in 2009 at the University of Pennsylvania. Additional areas of interest include adult orthodontic treatment, interdisciplinary treatment, improving treatment efficiency with TADs and craniofacial growth.

### Sergio Sambataro, DDS, MS, PhD

Dr. Sambataro received his D.D.S. degree from the University of Catania, and graduated from Catania University with an advanced specialty certificate and masters degree in Orthodontics; he also holds a PhD in Interceptive Orthodontics. While at Catania University, as

a researcher, Dr. Sambataro trained under Dr. Ricketts and received extensive experience in orthodontics and gnatology. Dr. Sambataro actively collaborated with Professor Robert Murray Ricketts at the American Institute for Bioprogressive Education in the development of new brackets and orthodontic wires, while studying facial growth and anthropology in depth. He translated scientific texts from English and he was lecturer and speaker at different Courses and Meetings in Brazil (São Paulo), Italy (Bari, Catania, Firenze, Messina, Reggio Calabria, Rimini, Roma, Verona), and Spain (Santiago de Compostela).

### Enrique García Romero, DDS

Dr. Enrique García Romero has been dedicated to the clinical application of the Bioprogressive Therapy and postgraduate teaching for the last 23 years. He is professor at the Universidad Central de Venezuela and Universidad de Carabobo. He is former president of the Sociedad Venezolana de Ortodoncia and currently lectures on Bioprogressive topics worldwide. His private practice is in Caracas, Venezuela and he is the developer of the easyceph® online digital cephalometrics. He is fellow of the WFO and AAO.


### Duane Grummons, DDS, MSD

Dr. Grummons is a Board Certified orthodontist who has lectured before most American orthodontic organizations and world-wide. His facial frontal analysis, TMD publications, and space gaining orthodontic appliance innovations are effective and extensively utilized. Dr. Grummons is internationally recognized for his clinically sensible approaches and knowledge base for jaw orthopedics, facial asymmetry, 3D Cone Beam leadership, TMD co-management, and non-extraction orthodontic treatments. Stunning smiles and facial harmonies are consistent outcomes of his treatments. Dr. Grummons is Associate Professor of Orthodontics at The Loma Linda University Medical Center Orthodontic Department. He has appeared before many dental, surgical and medical conferences, and has made radio/TV appearances. His orthodontic specialty practice is in Spokane, WA.



## PERSPECTIVE IN BIOPROGRESSIVE THERAPY

RUEL W. BENCH, DDS



A Bioprogessive symposium in August 2011 in Brazil attracted over 500 Orthodontists, where local Brazilian teachers and professors of Bioprogessive Therapy presented their current Bioprogessive treatment procedures. The French Ricketts Bioprogessive Society has over 700 orthodontist members. Bioprogessive lectures in Mexico attract very large numbers of Bioprogessive orthodontists. Bioprogessive Therapy is practiced worldwide.

This outpouring of interest in Bioprogessive Therapy began in the 1950's when Dr. Robert M. Ricketts attracted much interest in his early mixed dentition, non extraction treatment. His approach included his interest in growth, development and function as revealed from his study of the cephalometric x-rays.

Rick's treatment of young cleft palate children at the University of Illinois revealed the need for maxillary arch expansion in those cases, and practically all other malocclusions. His use of the lingual quad helix expansion arch invited additional variations that addressed the need to develop an expanded, more normal maxillary arch form.

Dr. Rickett's accidental penicillin-like discovery resulted in the ability to intrude the lower incisors, that previously were thought to be impossible to intrude. A tipped lower molar being uprighted against "the anchored lower incisors"

resulted in their being intruded. The key factor being a light continuous force, properly directed. In order to apply the lighter continuous forces that effected incisor movements, the multi-use utility arches that spanned from the molars to the incisors were developed. Bioprogessive Therapy promoted a concept of sectional arch therapy where breaking up the continuous arch wire allowed better control of the buccal occlusion, upper incisor torque and midline positioning.

Computerized cephalometrics as a diagnostic service was developed in conjunction with Rocky Mountain Orthodontics in 1968. This was a challenging new concept at the time, that today is accepted as a standard by the whole orthodontic profession. It brought a whole new concept to cephalometrics that proposed a coordinate axis from which growth and treatment changes could be better analyzed, and described the various facial types in their position along the bell curve.

Bioprogessive Therapy's use of the "Visual Treatment Objective" in treatment planning, has introduced us to the advanced management procedures that can help us achieve the quality results we desire.

In 1972, I proposed eleven principles to explain the basic concepts and treatment objectives of Bioprogessive Therapy. They have become a standard for over four decades.

**THE CROSS SECTION OF THE CHAMBERED NAUTILUS ILLUSTRATES THE LOGARITHMIC PATTERN THAT RICKETTS DEMONSTRATED IN THE GROWTH OF THE MANDIBLE**

## Principles of Bioprogessive Therapy

1. The use of systems approach in diagnosis and treatment by the application of the visual treatment objective in planning treatment, evaluating anchorage, and monitoring results.
2. Managing treatment to unlock the malocclusion in a progressive sequence and establish more normal function and growth.
3. The availability of torque control throughout treatment, thus edgewise brackets.
4. Muscular and cortical bone anchorage.
5. Movement of all teeth in any direction with the proper application of pressure (force per unit area).
6. Orthopedic alteration - point of control.
7. Treat the overbite before the overjet correction.
8. Sectional arch therapy with utility arch mechanics.
9. Concept of over treatment.
10. Efficiency in treatment with quality results, utilizing a concept of pre-fabrication of appliances.
11. Masticatory dysfunction (TMD) disorders managed.

**"Bioprogessive Therapy is not just a technique but applies biological principles in a progressive manner throughout the life of the patient."**

This concept has involved orthopedic changes, TMJ function and treatment, lighter controlled forces, brackets, appliances and arch wires that support and sustain the biological principles. Today's cone beam images, pin implant anchorage and other high tech applications lend support to our basic Bioprogessive Therapy.

Sharing Bioprogessive Therapy around the world and seeing its benefits appreciated has been very satisfying and Rocky Mountain Orthodontics has been a very supportive partner in these endeavors over the years.

# CONTEMPORARY BIOPROGRESSIVE THERAPY

NELSON OPPERMANN, DDS, MS



In 1950, Dr. Robert Murray Ricketts published “Variations of the Temporomandibular Joint as Revealed by Cephalometric Laminagraphy”, commencing the birth of the Bioprogessive Therapy. The orthodontic community in 1950<sup>1</sup> was introduced to an alternative perspective from the young and active mind of a postgraduate student at the University of Illinois, Dr. Robert Murray Ricketts.

After his initial publication, Dr. Ricketts completed more than 300 complementary articles and books that made their way into the orthodontic community. He only stopped publishing when he passed away on June 17th, 2003. During his journey he built a worldwide network of relationships and colleagues including Dr. Ruel Bench and Dr. Carl Gugino, both influential Bioprogessive maestros. The reach of Bioprogessive never ended, in fact it has grown, and currently there are many orthodontists around the world practicing Bioprogessive principles. These principles were generated and developed by Bioprogessive Therapy practitioners since the 1950s, but in 1979 Ricketts et al<sup>2</sup> stated some of them:

1.) **Using a systems approach to diagnosis and treatment, by applying the visual treatment objective (VTO), evaluating anchorage and monitoring results.** The Bioprogessive Therapy advocates that it is imperative to implement a comprehensive diagnostic analysis of the malocclusion to be treated, taking into account the face and skull. It is imperative to utilize both lateral and postero-anterior radiographs.

It's important to focus on seven key parameters of the lateral analysis: a) Anterior Cranial Base, b) Posterior Cranial Base, c) Mandible, d) Maxilla, e) Upper Teeth, f) Lower Teeth, g) Soft Tissue. Always keep in mind adaptation of the outcome for each patient individually with attention to: genetics, environment, and individual factors.

2.) **Maintain torque control throughout treatment.** This is of great value during the mechanics phase of treatment, especially in the vertical dimension.

3.) **Understand muscular and cortical bone anchorage.** Understand the limits of orthodontic mechanics and apply this concept to control the case orthopedically,

respecting and comprehending the intrinsic limits of each individual's biology and orthopedic function. Mesofacial, Brachyfacial and Dolichofacial patients require distinct anchorage needs.

4.) **Movement of all teeth in any direction with the proper application of pressure.** Observe the root surface proportions of every tooth to be moved.

5.) **Orthopedic alteration/skeletal dysplasia.** Bioprogessive Therapy indicates a proper understanding of the mandible and its adverse reaction to abnormal function, such as cross-bites and deep overbites. Correcting these problems is fundamental in order to have a positive reaction on the mandible and a normal direction of growth, leading to a pleasant profile. Bioprogessive Therapy emphasizes careful observation of the functional occlusal plane. The occlusal plane is a great indicator that orthopedic problems may occur, leading to clockwise (poor) growth of the mandible. Mandibular ramus height, the direction of the growth in the condyle, and the amount of growth of the coronoid process, are all strong indicators if the patient's face is growing

in a physiological growth pattern or not. When abnormal growth exists, the mandible always reacts poorly and suffers the most.

6.) **Treat the overbite before the overjet.** The mandible reacts positively (movement in a counterclockwise direction) when it does not encounter anterior / incisor interference. Using bite jumper appliances, or Class II elastics on deep over-bite cases before opening the bite can lead to one of the most common clinical mistakes in orthodontics. Using these appliances before opening the bite can cause interference and premature contacts between the incisors.

7.) **Sectional arch approach. It is logical to design treatment mechanics using a sectional arch approach.** Dividing the upper and lower arches in sections, separating the molars, bicuspid, canines and incisors simplifies the mechanics. Working with the sections of the upper arch and lower arch in the transverse, then vertical, and finally horizontal dimension; sets up the case for using Straight Wire mechanics to create an ideal finish for the case.

8.) **Overtreat.** Overtreatment of the case insures long-term stability. Always keep in mind that we are working with periodontal ligaments, periosteum, sutures, and muscles. These structures tend to return to their original condition and it's important to note the possibility of rebound in the case.

9.) **Unlock the malocclusion in a progressive sequence in order to establish or restore normal function.** Treating the case in the transverse dimension before the vertical dimension, and the vertical dimension before the horizontal dimension, naturally and biologically unlocks the malocclusion in a progressive manner. This provides the opportunity for the bony structures and the dentition to adapt to a more natural condition and preserve healthy TMJs.

10.) **Utilize quality-fabricated appliances for efficiency and quality results.** Bioprogessive Therapy continues to adapt modern technology and materials, always respecting the fundamental principles indicated in this article.

“The reach of Bioprogessive never ended; in fact it has grown, and currently there are many orthodontists around the world practicing Bioprogessive principles.”



All of the concepts in this article can be applied to diagnostics and treatment mechanics for every case, utilizing them to design the Visual Treatment Objective (VTO) before any fixed appliance treatment. By using lateral and frontal cephalograms, and starting with the end of treatment in mind, provides the practitioner with the best opportunity for success and avoids any unforeseen events during treatment. In order to fully understand cephalometrics, the clinician must start by understanding normal growth concepts. Then, apply the concepts of proportions, observing principles of “The Golden Proportions”.<sup>3</sup>

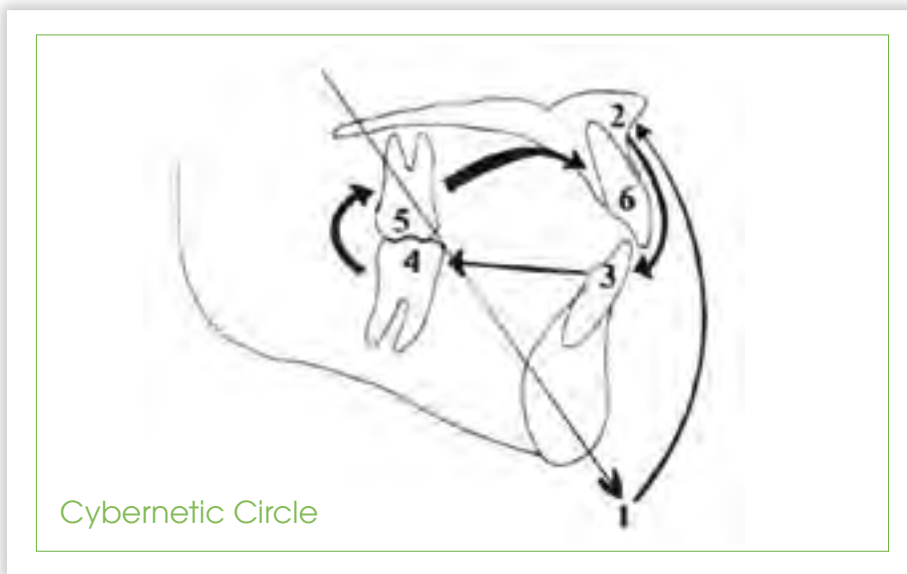
During the phase of working mechanics, follow the idea of progressive mechanics. Start in the transverse dimension using expansion devices, employing rapid or slow palatal expansion (depending on the amount of forces desired). As an example, we use the Wilson 3D Quad Helix, a prefabricated appliance, to work in the transverse dimension. The great benefit of this system is the complete 3D control of both torque and rotation of the molars during treatment. Since the appliance is removable by the orthodontist, the results are completely predictable. This is a great example of how Bioprogressive principles can be applied using many different types of appliances.

After addressing the transverse dimension, work in the vertical dimension by using appliances such as cervical headgear to control vertical posterior dimension on growing patients and the utility arch to control the vertical anterior position. In order to control the vertical posterior dimension it is necessary to have full control of anchorage in the lower first molars. Tip back, toe in, and torque bends can be applied to maximize anchorage. The use of sectional mechanics to stabilize the arch from first molars to the bicusps or canines is fundamental in Bioprogressive Therapy to avoid undesirable tip back of the molars. TADs can also be used to help reinforce the anchorage system. Any type of new alloy or technology can be used in the Bioprogressive Therapy as long as the basic principles are maintained. For example, the use of nickel titanium or TMA alloys to retract canines is great, keeping in mind the amount and direction of the counter forces produced using these types of materials.

After establishing treatment goals in the transverse and vertical dimensions, the mandible adapts to a more natural forward position. Often the horizontal dimension will need to be addressed in order to drive the case into its finishing stage. There are a variety of options for this phase such as Class II elastics, upper molar distalization and/or mesialization of the lower molars. The decision to utilize one type of mechanics versus another will be based on the information received using the VTO.

When working on the VTO, it is imperative to recognize and completely understand the relationship and

it (2). After addressing the mandible and A Point it's possible to design the new A-Po plane. Using the new A-Po plane as a reference, place the lower incisors in the correct position (3). Next, place the lower molars, keeping in mind the lower arch depth and the type of lower anchorage needed. Any movement of the lower molars forward, or burning anchorage, will tend to rotate the mandible in a counterclockwise direction (4). Once the lower molar position is identified, place the upper molars according to the treatment plan, typically in a Class I relationship. If the case requires distalization of the upper molars the mandible will tend to rotate in a clockwise direction (5).



interaction of dental and skeletal changes. This is described by a circle of reactions named by Dr. Ricketts as the “Cybernetic Circle”, first presented in 1976.<sup>4</sup>

Before placing bands and brackets, the practitioner should have a full understanding of the “Cybernetic Circle”. Keeping the end of treatment in mind and visualizing the actions and reactions of soft tissue and hard tissue helps organize ideas and predicts how treatment will impact the patient.

An example of how to understand the Cybernetic Circle is to start with the position of the mandible (1). After positioning the mandible in the sagittal plane, the 2nd step is to place A Point and understand the mechanics that can affect

Next, check the upper incisor position, adjusting torque and intrusion according to the facial typology. Use the Facial Axis as a reference to place the incisor inclination (6).

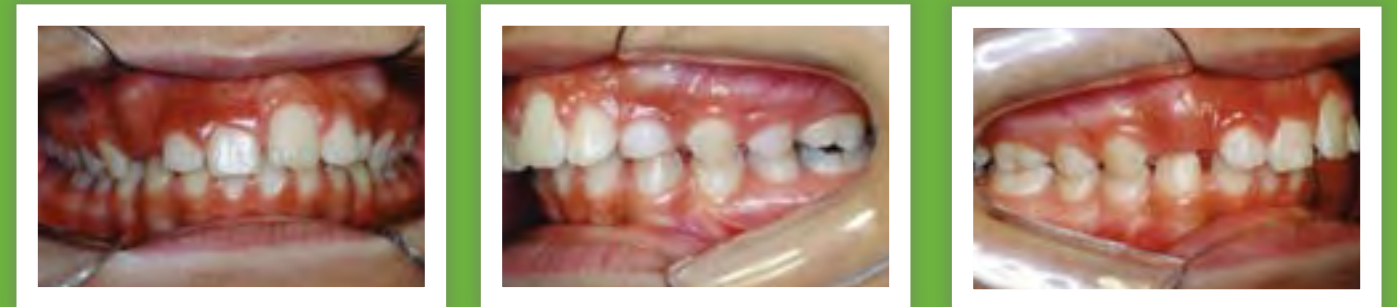The following clinical case shows how to apply biomechanics using the principles of the Bioprogressive Therapy and the “Cybernetic Circle.”

“During the phase of working mechanics, follow the idea of progressive mechanics.”

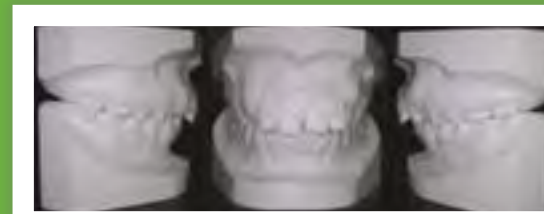

PATIENT: MIXED RACE, FEMALE, 12 Y AND 02 M OF AGE.

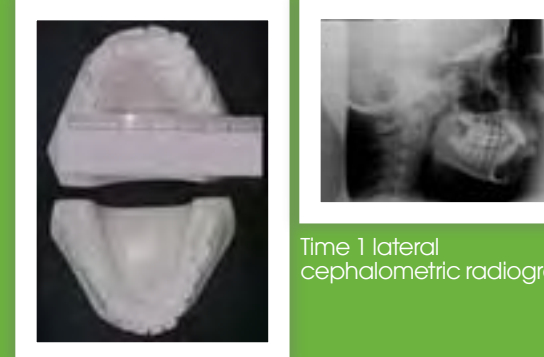CHIEF COMPLAINT: PROTRUSION, CHIN BACKWARDS AND SPACING.



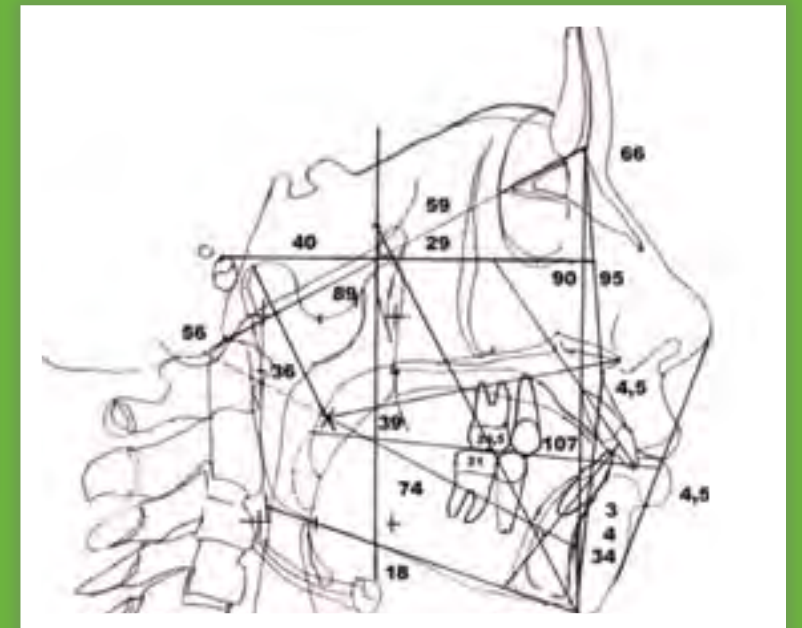
Patient's initial pictures, showing lip incompetence and convex profile.



Stone casts models at the beginning of treatment



Time 1 lateral cephalometric radiograph.



Time 1 lateral cephalometric tracing and Ricketts analysis.

Stone casts models at occlusal view, showing a nice upper molars, transverse dimension of 57mm.

# As good as it gets

RMO®'s Energy Chain™ is the proven leader in elastomeric chain material, outperforming other elastic chains in numerous independent clinical tests. Stain resistant, latex free, 4 sizes and a variety of colors.



RMO®'s patented formula provides light, continuous force for weeks resulting in brilliant closure and very..very..happy patients.



Energy Chain™



A summary of the records presents a brachyfacial growing patient with skeletal and dental deep overbite. The mandible is well positioned but the maxilla is positioned forward to Frankfort, indicating a mild Class II skeletal position. The Facial Axis is showing a slight counterclockwise rotation, which is not normal on brachyfacial patients. The upper molars can be distalized, indicated by large upper molars to PTV line distance. The incisors are protruded, indicating extrusion of the upper incisors. Lower incisors are well positioned for a brachyfacial typology. The profile is convex and poor, indicated by 4.5mm of lower lib to E-line. The stone models indicate that this patient does not need arch expansion, the upper molars are well rotated and both arches have good general spacing.

After careful study of all the records, there are several options of how to treat this case. Possible options include:

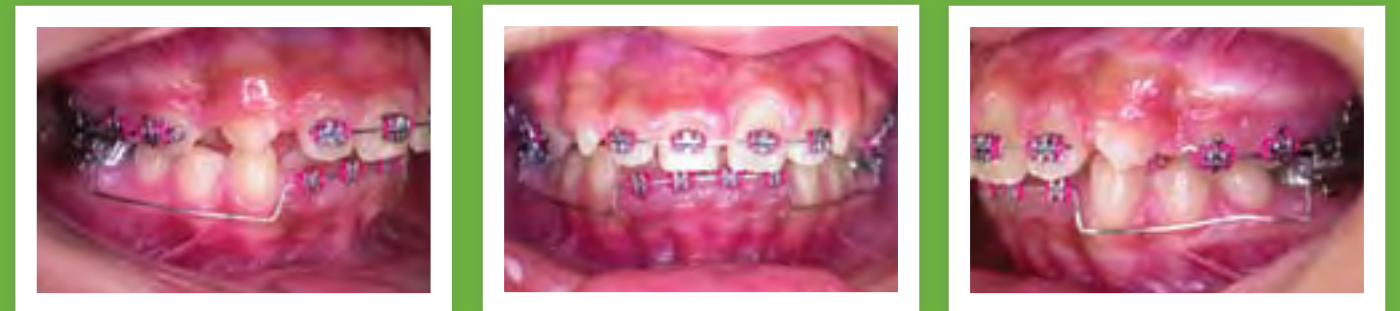Option #1) Distalize upper molars. This approach would treat the dentition very well and provide an aesthetic smile. However, it will not change the profile of the patient. The patient would finish with a Class II profile (convex) at the end of treatment.

Option #2) Four bicuspid extraction. Because of the general spacing already present in the case, extracting four bicuspids would make it more difficult to close space later in treatment. Additionally, extracting the bicuspids would amplify the facial typology and make it very difficult to control the vertical dimension during the retraction of the incisors.

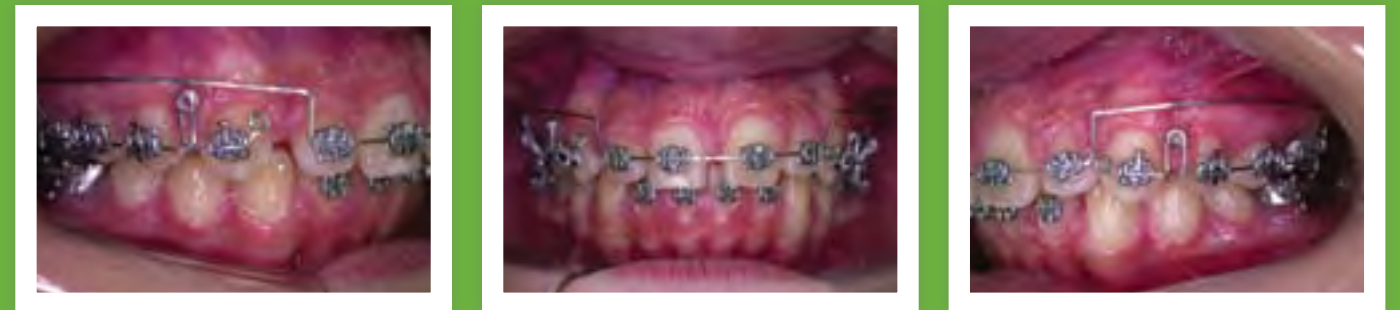
Option #3) Upper first bicuspid extractions. This approach would fix the overjet issue, but it would not resolve the convex profile. Finishing the case with a Class II molar relationship would make it harder to have a well balanced occlusion.

Option #4) Burn lower molar anchorage. This approach corrects the molar relationship and moves the posterior teeth forward, rotating the mandible in counterclockwise direction, improving the profile and addressing one of the patient's chief complaints. In order to accomplish this approach it is imperative to control the upper incisor extrusion, avoiding incisor proprioception by opening the deep overbite.

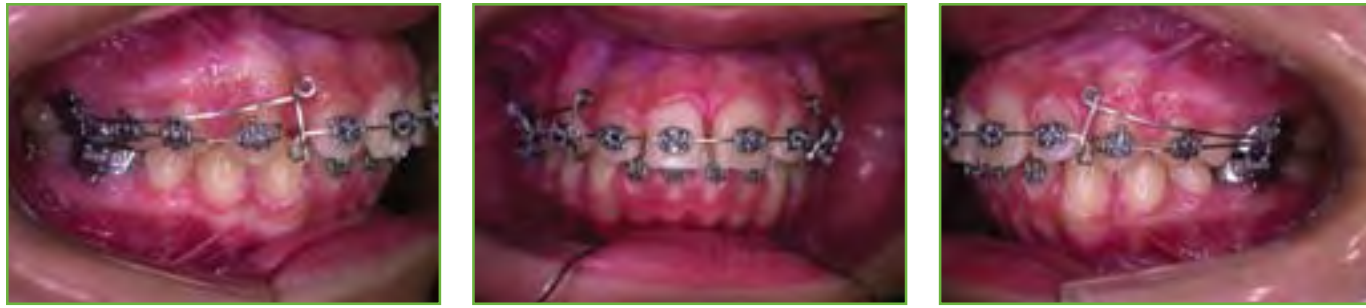Option #4 was implemented and the treatment sequence and biomechanics are below:



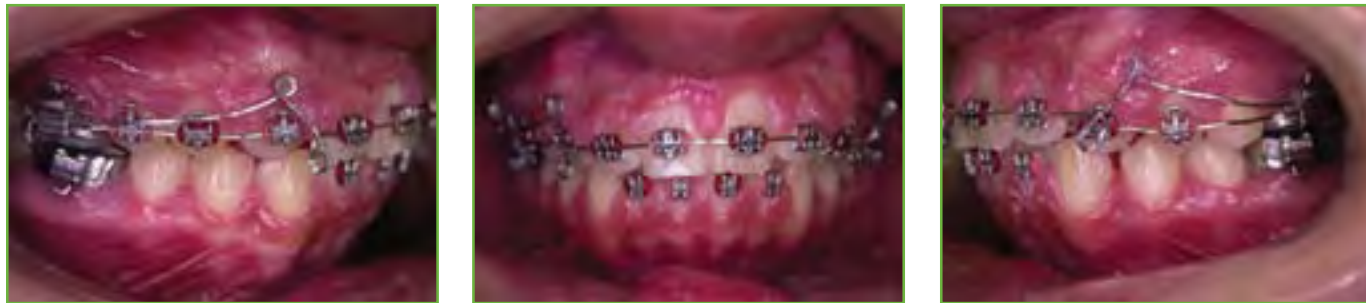Lower Utility Arch was used to control the lower incisors. Synergy brackets Ricketts prescription (.0185 x .030) were used. Sectional arches on the upper arch and Class II 3/16" elastics were placed from upper first bicuspid to the lower first molars.



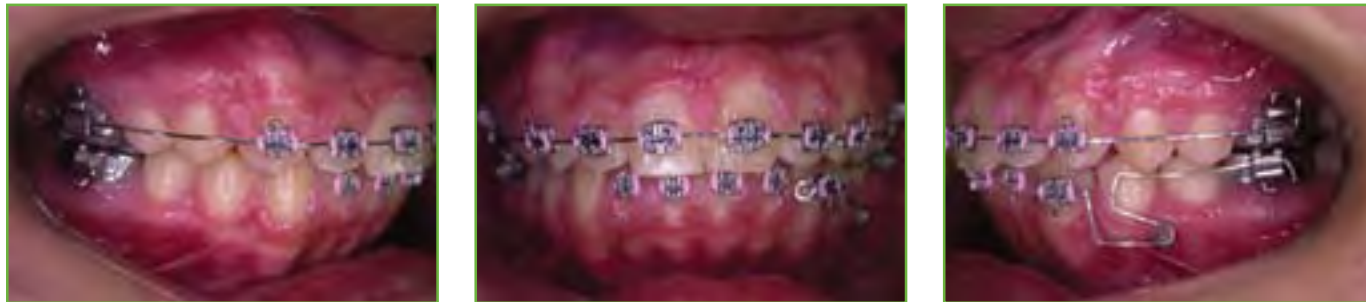After achieving Class I molar relationship, retraction arches were placed on the canines. An upper Utility Arch was placed to reinforce the anchorage. Lower Utility Arch was removed and only four brackets and two bands were used to treat the lower arch.



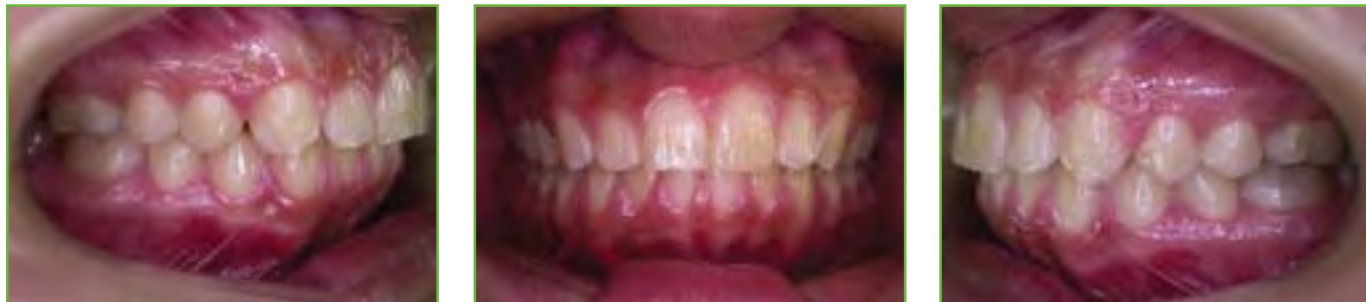Upper incisor retraction starts after achieving Class I canine and molar relationships. Because the case required careful attention to control torque and intrusion for the upper incisors, it was decided to retract with a contraction Utility Arch.



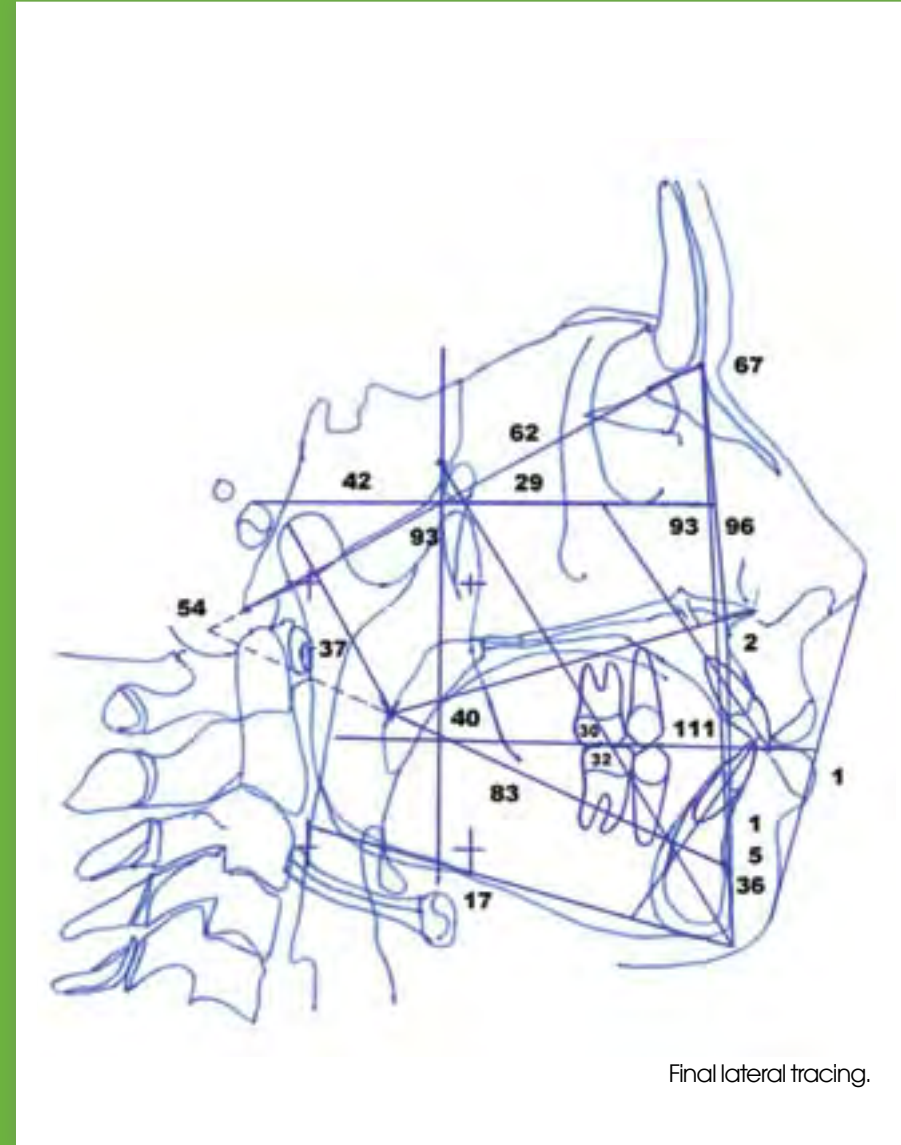
The finishing of upper incisor retraction.



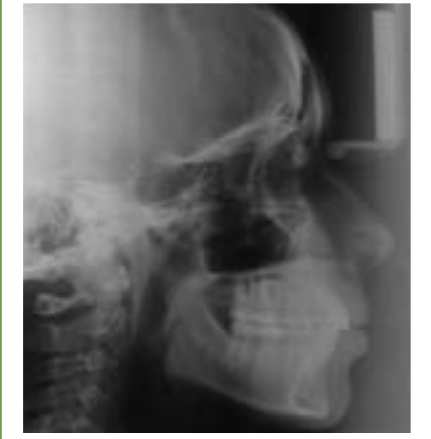Pictures showing the finishing and detailing stage. "L" sectional spring was placed to improve the position the lower left canine.



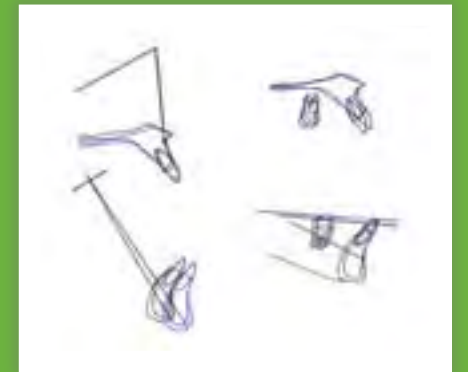It's recommended to finish Class II div. 1 growing Meso to Bracyfacial typology patients with a mild overjet of 2mm – 3mm in order to leave room for the mandible to keep growing in the proper direction. This helps avoid Class II relapse or future crowding in the lower anterior region. The patient will reach adulthood with a healthy oral environment.



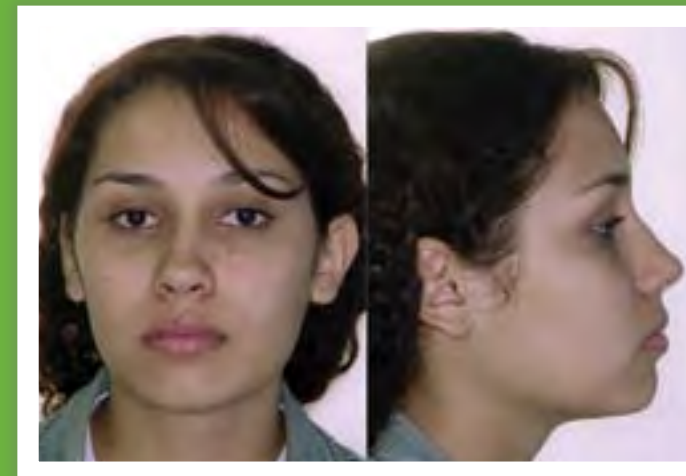Final lateral tracing.



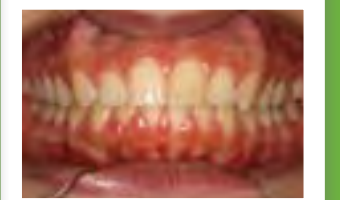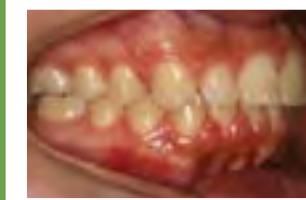Final lateral cephalometric radiograph.



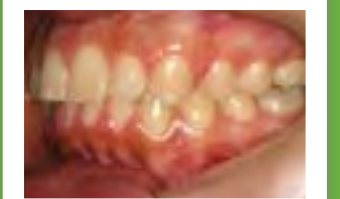Before and after superimpositions. Note the amount of counterclockwise rotation of the mandible. Lower molar anchorage was burned which promoted the forward movement of the mandible. Upper molars did not drift mesially and upper incisors were retracted while carefully controlling the torque.



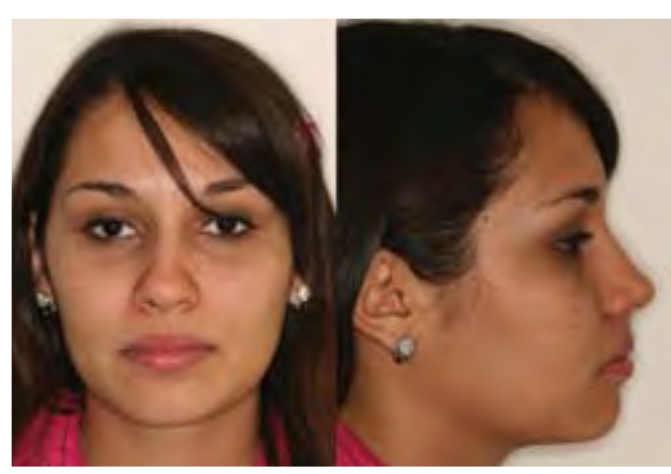Pictures showing the face at debond. Note the profile improvement.



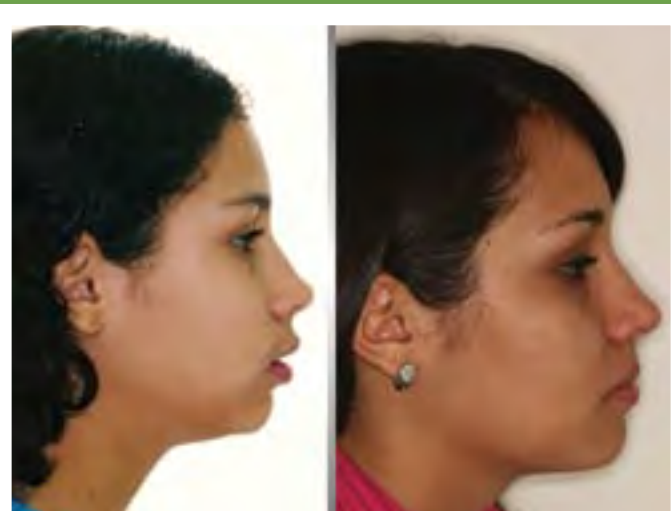
Four years post treatment. The mandible continued to move forward and the overjet has disappeared.







Photograph after 4 years into adulthood.



Before and after profile changes. Mandible has rotated in a favorable direction and significantly improved the patient's profile, and fulfilled her treatment expectations.

Conclusions: The Bioprogressive Therapy is not a "technique". It is a method of how to approach an orthodontic case based on biological principles and customized biomechanics. New brackets designs, new wires alloys, and new devices can be developed and used with this method as long as all of the principles described in this article are followed. The practitioner can choose to integrate technology into this approach and take advantage of all benefits these technologies have to offer to orthodontics and dentofacial orthopedics.

**REFERENCES**

1. Ricketts RM. Variations of the temporomandibular joint as revealed by cephalometric laminagraphy. Am J Orthod, St. Louis, v. 36, no. 12, p. 877-898, 1950.
2. Ricketts RM, Bench RW, Gugino CF, Hilgers JJ, Schulhof RJ: Bioprogressive therapy, Book I, Denver, 1979, Rocky Mountain Orthodontics.
3. Ricketts, R.M. The biological significance of the divine proportion and Fibonacci series. Am J Orthod. 1982;81:351-370
4. Ricketts RM. Bioprogressive therapy as an answer to orthodontic needs part 2. Am J Orthod, St. Louis, v. 70, no. 4, p. 358-397, 1976.
5. Ricketts RM. et al. Orthodontic diagnosis and planning – their roles in preventive and rehabilitative dentistry. Rocky Mountain Orthodontics, [s.n.],1982. v.1, p.269.

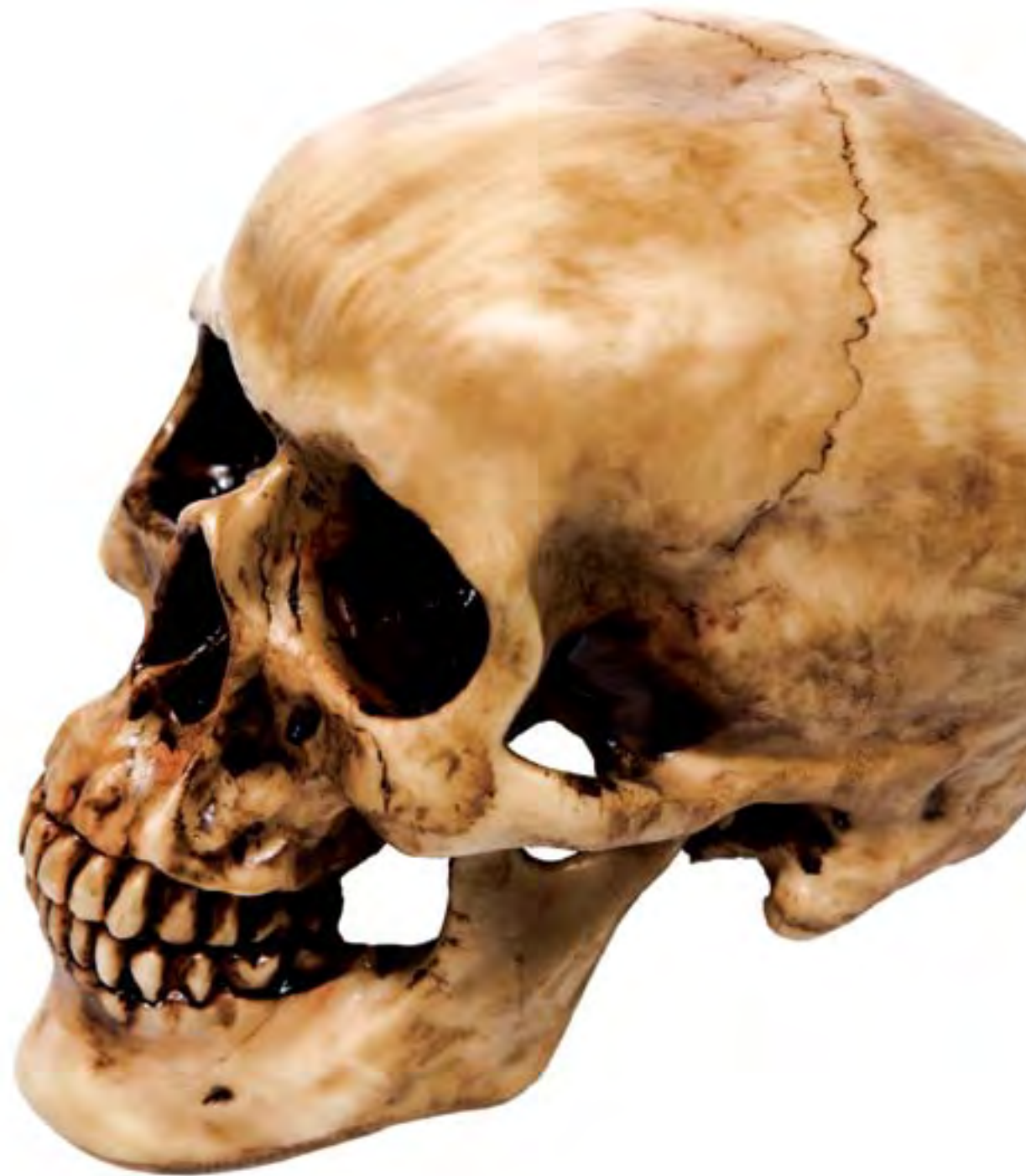

**FlashMax P3  
Light Pen**

The world's most powerful curing light.  
Redesigned and loaded with new functions.

**FlashMax P3  
Light Pen**





“These adverse periodontal responses with RPE highlight the importance of early treatment.”

## RAPID MAXILLARY EXPANSION WITH SKELETAL ANCHORAGE VS. BONDED TOOTH/TISSUE BORN EXPANDERS: A CASE REPORT COMPARISON UTILIZING CBCT

ROBERT L. VANARSDALL JR., DDS, IGNACIO BLASI JR., DDS, MARIANNA EVANS, DMD, PAUL KOCIAN, DDS

The CBCT provides three dimensional representation of the facial structures including the basal bone of the maxilla. Maxillary hypoplasia has been an important indication for early treatment.

Unfortunately, RPE has been used primarily to treat dental crossbites or for gaining space to prevent extraction with little or no attempt made to coordinate the transverse skeletal patterns<sup>1</sup>. Traditional maxillary orthopedics has been done using the dental units as anchorage, for example, Haas and Hyrax<sup>2</sup>. Dental movement has not only limited skeletal orthopedic change, but has caused significant adverse periodontal and instability side effects<sup>3</sup>. There is a clear correlation between buccal tooth movement and gingival recession and bone dehiscences. These adverse periodontal responses with RPE highlight the importance of early treatment. The beneficial periodontal effects of transverse skeletal correction have been a main focus of our research for the past 35-40 years<sup>4</sup>. Krebs used implants to evaluate orthopedic expansion and confirmed 50% dental movement and 50% skeletal movement in children. In adolescence, however, only 35% of movement was skeletal and 65% was dental<sup>5</sup>. In addition, it is well known that as the patient grows older, dental tipping with RPE becomes greater, which puts teeth at higher risk for gingival recession. We have emphasized the importance of correcting transverse skeletal discrepancy<sup>4</sup>:

- A. To prevent periodontal problems.
- B. To achieve greater dental and skeletal stability.
- C. To improve dentofacial esthetics by eliminating or improving lateral negative space.

When it may be critical to saving the natural dentition, we do not want to introduce adverse dental/skeletal changes, in adolescents and/or patients with advanced periodontal disease. In theory, skeletal anchorage should permit orthopedic change without adverse dental changes by applying force directly to the maxillary bone<sup>6</sup>.

With all the emphasis on evidenced based orthodontics a most recent CBCT randomized clinical trial (14 years old) has reported that bone- anchored maxillary expanders and traditional (Hyrax) rapid maxillary expanders showed similar results. The tooth born group exhibited more first premolar expansion than the bone anchored appliance and both exhibited significant increase in crown inclinations<sup>7</sup>.

The purpose of this report is to compare the treatment response of patients with equivalent skeletal severity, sex and similar age from our most effective orthopedic tooth/tissue born expander and the bone anchored maxillary expander on the basal bone and the molar teeth.

### Materials and Methods

Two 14.5 year old twins with maxillary transverse deficiencies (treated in the orthodontic clinic at the University of Pennsylvania) were chosen to be treated; one with a bone screw anchored RPE and the other with a tooth-tissue born appliance (Fig 1-2).

A pretreatment cone beam CT image was taken before treatment (T1). Scans were obtained using an I-CAT machine for both patients. The bonded maxillary expander was cemented into place and had

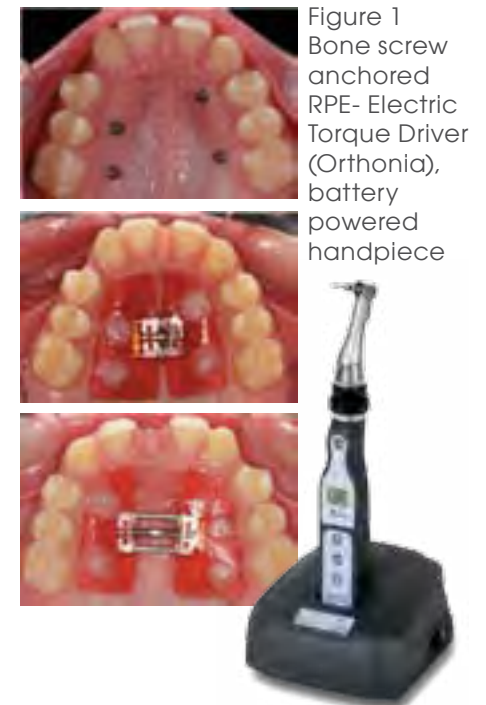

Figure 1 Bone screw anchored RPE- Electric Torque Driver (Orthonia), battery powered handpiece

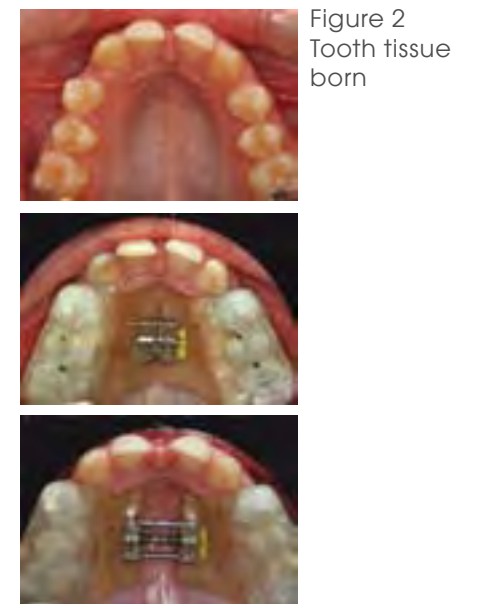


Figure 2 Tooth tissue born

full occlusal and palatal acrylic coverage. Appliances for both twins were made by the same laboratory. Expansion was carried out with two turns per day (0.2mm per turn) for as long as necessary until the required expansion was completed to normalize the transverse dimension. Post expansion cone beam CT image was taken the day the expander was stabilized, (T2). Post-treatment I-CAT scan had a reduced window and decreased radiation by 1/2 (20 sec. to 10 sec.).

Neither patient received orthodontic movement on the maxillary arch until T2 records were taken.

The CT images were obtained without the patient positioned in a head positioner, therefore before the images were measured, each image was oriented using Anatomage InVivoDental software. The skulls were oriented in three planes of space using frontal view, right lateral and left lateral view. The head was oriented in the frontal view with the floor of the orbits parallel to the floor. The right lateral view allowed placement of the skull so Frankfort horizontal was parallel to the floor. Both right and left posterior borders of the ramus and angle of the mandible were superimposed on each other to the best possible fit. The left lateral view was also examined to ensure Frankfort was parallel to the floor and the border of the ramus and angle of the mandible were superimposed as best fit<sup>8</sup>.

### 3D Skull Measurements

The measurements were calculated from a 3D Skull view of the patient. Points 1 and 2 are reference points that serve to represent the level of basal bone of the maxilla (Fig. 3). These landmarks are defined as the most superior aspect of the concavity of the maxillary bone as it joined the Zygomatic process. Figure 4 shows pre and post expansion at the first molar and red lines indicate axial inclinations of the molars<sup>9,10</sup>.

### Results

The CBCT technology allows for more reliable and accurate measurements for distances between subject's anatomical landmarks<sup>11</sup>. The maxillary basal change with the skeletal/ bone anchorage device was significant without dental compensation.

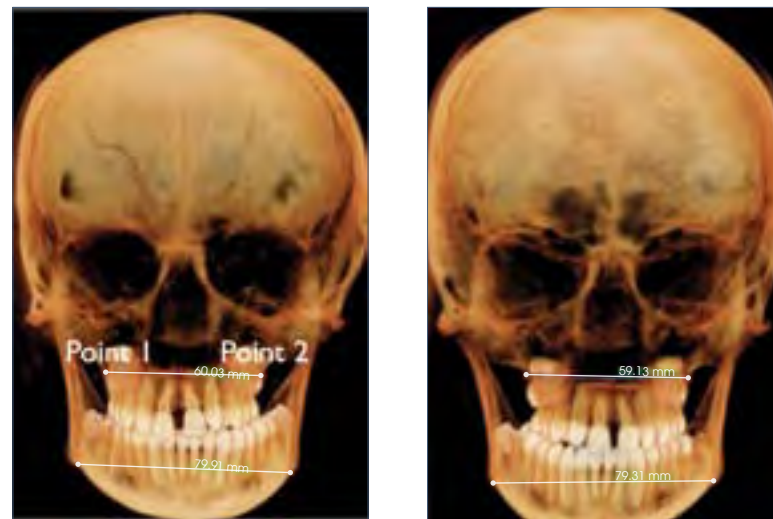


Figure 3- Before Treatment

### Basal Bone

There was a significant increase in width of the basal bone as a result of the palatal expanders.

Comparing skeletal anchorage vs. dental/palatal tissue treatment expansion efficacy both demonstrate significant skeletal change. But the

skeletal anchorage device achieved significantly more skeletal change (MX-MX) without dental compensation than did the dental/palatal anchorage device. Approximately 3mm greater basal maxillary expansion was noted with skeletal vs. dental/palatal anchored RPE (Fig. 4).

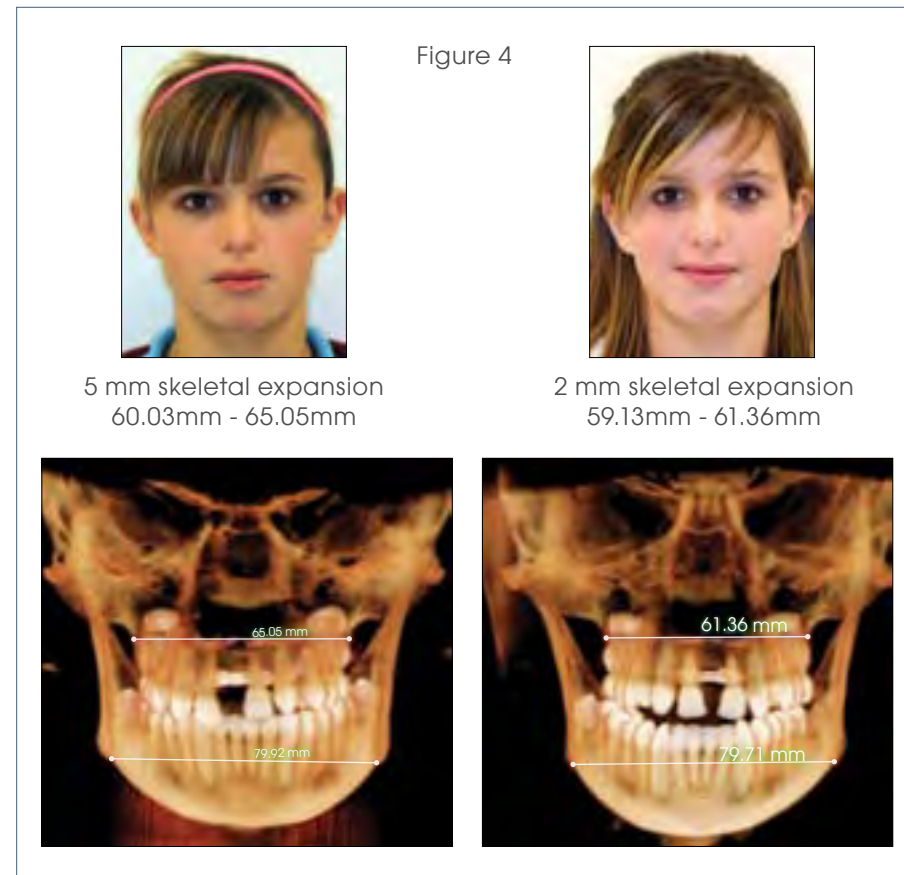

Figure 4

### Molar Tipping

A significant difference was seen in the increase in the molar tipping (Fig. 5). No tipping was noted with the skeletal anchorage RPE and significant dental tipping was exhibited by the dental/palatal RPE.

### Evaluation of Findings

As interesting and clinically important as these preliminary findings are, this report is only on two identical patients. The findings with bone anchorage demonstrates pure skeletal expansion without dental compensation (Fig. 6-7-8). RPEs with skeletal anchorage have been used to reduce surgery from 2 jaws to 1 jaw in a large number of cases. But well designed randomized controlled clinical trials with large numbers of moderate to severe transverse skeletal discrepancy that may be contraindicated for dental/palatal expansion should be evaluated to delineate reproducible treatment potential. Significant evidence in this regard will be reported in the future.

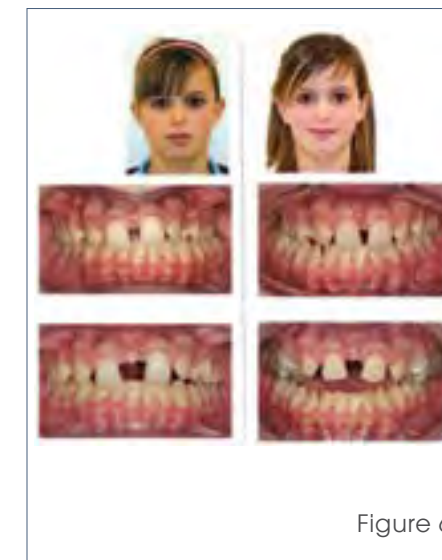


Figure 6

There was a significant increase in width of the basal bone as a result of the TAD palatal expander.

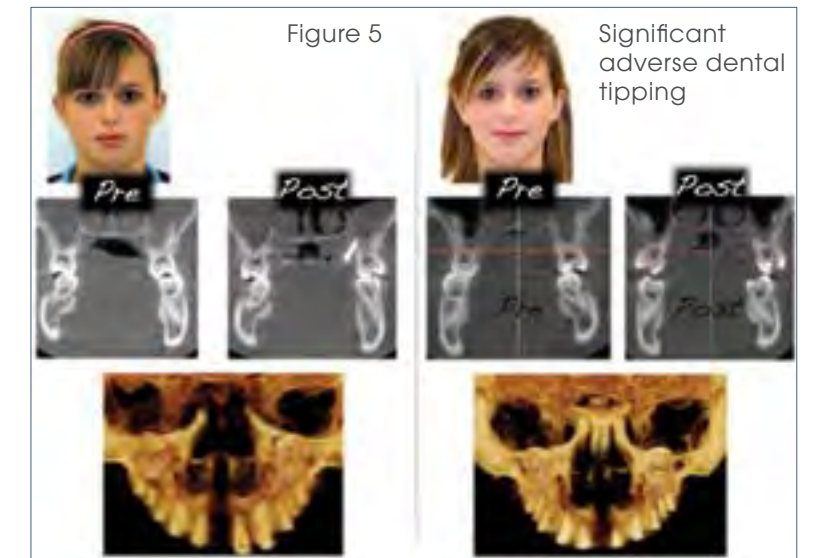


Figure 5

Significant adverse dental tipping

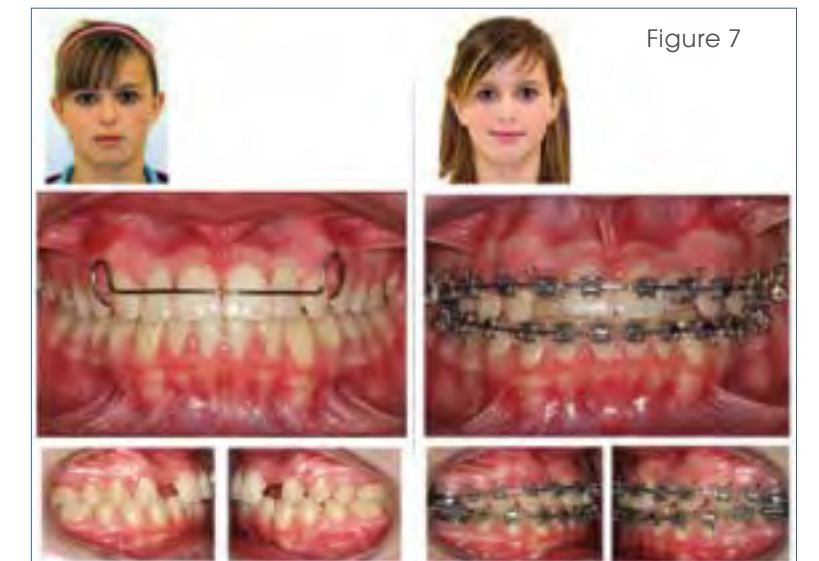

Figure 7

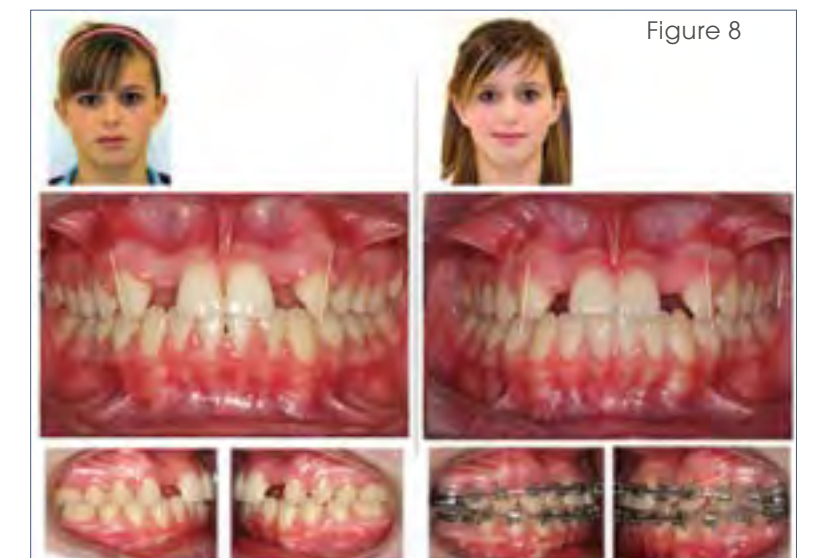

Figure 8

Discussion

The literature and our initial findings have suggested that a greater magnitude of orthopedic change and minimal dental movement are possible. Both twins exhibited significant expansion at the level of the maxillary first molar crown and root apex. Axial slices indicate the bonded tooth/tissue patient as well as the bone anchored patient exhibited midline suture opening in a parallel fashion. This was different from earlier expanders which have been reported to cause openings of the midpalatal suture in the area of PNS occurring at a lesser extent than at ANS.

Oliveira et. al examined the different effects of a tooth tissue born appliance (subjects with a mean age of 11.9 years) with a tooth born only appliance (subjects with a mean age of 11.1 years). They reported that the tooth tissue born expander demonstrated more orthopedic movement and less dentoalveolar tipping<sup>12</sup>.

The CBCT technology allowed for clear visualization and quantification of the changes in basal bone associated with palatal expansion<sup>11</sup>. In fact, the high precision of the quantitative analysis on CT images contributes to the reliability of this outcome and makes this case report more acceptable.

“These results indicate that clinicians can predictably achieve at least 3 mm or more of pure skeletal change using skeletal anchorage expanders in older more mature patients.”

In practice the skeletal anchorage may not be necessary in mild transverse discrepancy due to the more invasive nature of placing the bone pins, potential failure and financial cost. In milder discrepancy cases, the dental/palatal anchorage still remains the best choice. The skeletal anchorage could be reserved for moderate to severe cases, periodontally involved, missing teeth or where the dental/palatal expander is

guarded or anticipated but the patient or clinician does not want to commit. It may provide an alternative to surgery.

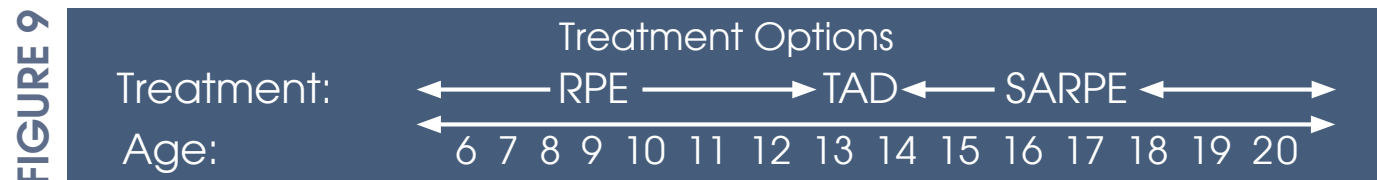We are presently conducting clinical trials to determine the limit of skeletal anchorage and palatal expansion.

Conclusions

Based upon our present studies and treatment to normalize transverse skeletal discrepancy a clinician could anticipate at least 2-3 mm greater basal expansion with the skeletal anchored RPE than with the tooth tissue born RPE.

The skeletal anchored RPE produced less molar tipping than the tooth tissue born RPE.

The palatal skeletal change that is predictably possible remains unknown and future research is needed. But it is clear that the envelope of discrepancy has been changed for older patients (Fig 9).



References

1. Gianelly A.: Rapid palatal expansion in the absence of crossbites: Added value? Am J. Orthod Dentofacial Orthop 124:4, 2003.
2. George C. Chung C and Vanarsdall R.: Dentoalveolar inclinations with Hyrax and Haas palatal expander: evaluation using computer assisted tomography. Thesis, Department of Orthodontia, University of Pennsylvania, 2000.
3. Garib DG, Henriques JFC, Janson G, et. al.: Periodontal effects of rapid maxillary expansion with tooth-tissue borne and tooth borne expanders: A computed tomography evaluation. AJO-DO: 129: 749-758, 2006.
4. Vanarsdall, R and Secci, A: Chapter 23 Periodontal-Orthodontic Interrelationships, In Orthodontics- Current Principles and Techniques, Fifth Ed., Elsevier Inc, p. 807-841, 2011.
5. Krebs A.: Midpalatal suture expansion studied by the implant method over 7- year period. Trans Eur Orthod Soc, 40: 131, 1964.
6. Garcia J, Secci A, Vanarsdall R. “ Anclaje esqueletico Y Anclaje dentario,” Revista Socied Ad Espanola Orthodoncia, 51. No.1 50-58, 2011.
7. Lagravère M, Carey J, Heo G, Toogood R, Major P. Transverse, vertical, and anteroposterior changes from bone-anchored maxillary expansion vs traditional rapid maxillary expansion: A randomized clinical trial. Am J. Orthod Dentofacial Orthod. 137:304, 2010.
8. Christie, K.: Effect of bonded (tooth-tissue) RPE on the transverse dimension of the maxilla- A CBCT Study, Thesis, University of Pennsylvania, May, 2008.
9. Podesser B, Williams S, Grismani A, and Bantleon H-P: Evaluation of the effects of rapid maxillary expansion in growing children using computer tomography scanning: a pilot study, Europ J of Orthodontics 29: 37-44, 2007.
10. Kilic N, Oktay H. A comparison of dentoalveolar inclination treated by two palatal expanders. Eur J Orthod 30: 67-72, 2008.
11. Garrett, BJ, Caruso JM, Rungcharassaeng K, Farrage JR, Kim JS, and Taylor GD: Skeletal Effects to the maxilla after rapid maxillary expansion assessed with cone-beam computed tomography, AJODO: 134:8, 2008.
12. Oliveira NL, Da Silveira AC, Kusnoto B, Viana G,: Three dimensional assessment of morphologic changes of the maxilla; a comparison of 2 kinds of palatal expanders. Am J. Orthod Dentofacial Orthod. 126; 354-362, 2004.

# EAST MEETS WEST

New York University Langone Medical Center, Institute of Reconstructive Plastic Surgery, Partners with RMO® for fellowship program




First ADA Accredited Craniofacial and Special Needs Orthodontics Fellowship

NYU and RMO® collaborating to show how partnerships can shape lives



# CONTROL OF VERTICAL DIMENSION DURING SAGITTAL ORTHOPEDIC CORRECTION: THE DEATH OF THE WEDGE EFFECT THEORY AND THE BIRTH OF THE DECOMPRESSION THEORY

SERGIO SAMBATARO, DDS, MS, PHD



Extra oral forces have been used for several clinical applications during the last century.<sup>1-3</sup> In 1947, Kloehn<sup>4</sup> used cervical headgear to treat class II malocclusions. The main effect of this appliance was evident when it was used to produce skeletal alteration in the growing patient. During the last 50 years, several authors reached opposite conclusions about the effects of this appliance on the vertical dimension.<sup>5-50</sup>

Schudy,<sup>7</sup> and Creekmore<sup>11</sup> considered the responsible factor of the mandibular postero-rotation, especially in dolichofacial patients, to be the extrusive component. To prevent this effect, many clinicians started to use “high pull” traction to intrude the upper molar during Class II correction in hyper divergent patients, and relegated cervical traction to brachyfacial patients. Both, the “high pull” and the “low pull”, were used in mesofacial patients. This was the birth of the “wedge effect theory”<sup>11,12</sup> based on anecdotal cases without scientific data. Consequently, in our opinion, the incorrect use of cervical traction drives the orthodontic profession to believe that facial height increase is a side effect of cervical traction.<sup>5,6,8-10,12-21,27-29,32,33,37,40</sup>

Ricketts<sup>22,23,46-48</sup> and others<sup>24-26,30,31,34-36,38,39,41-45,49,50</sup> followed Kloehn’s indications and noticed good vertical control without mandibular postero-rotation.

Ricketts<sup>22,23,46-48</sup> asserts that cervical traction promotes a downward and backward displacement of the maxillary complex and through a modest extrusion of the upper molar, an increase of the vertical growth of the mandibular ramus with a consequent bite closure and without unfavorable mandibular postero-rotation.

Furthermore, Ricketts<sup>22,23,46-48</sup> advocates the use of a lower utility arch to open the bite in deep bite patients to prevent anterior interference, which is in part responsible for the mandibular postero-rotation.

The goals of this research are: 1) to determine the correct use of cervical

headgear to control the vertical dimension during Class II correction in the growing patient; and 2) to determine the dentoskeletal response in a) open bite patients when lower incisor intrusion is treated by cervical headgear and b) deep bite patients when treated with a combination of cervical headgear and a lower utility arch to open the bite by lower incisor intrusion. This is performed according to orthopedic Class II therapy as suggested by Ricketts.<sup>46-48</sup>

Strengths of this study include: 1) using untreated Class II patients and 2) appraisal of stages in individual skeletal maturity by the cervical

vertebral maturation (CVM) method.<sup>51</sup> Orthopedic and orthodontic effects were estimated using lateral cephalometric head film.

### Patients and Methods: Cephalometric analysis

41 measurements, 25 linear and 16 angular, were taken on the lateral headfilm; 37 were selected from the Ricketts Analysis<sup>52-58</sup> and 4 were suggested by Baccetti et al.<sup>59</sup>

The linear and the angular measurements are reported in Table I.

	FUNCTION	PARAMETER
1	Total Facial Height (TFH)	Corpus Axis ^ Basion Nasion
2	Lower Facial Height (LFH)	Corpus Axis ^ Org Line
3	Central Facial Direction (FAX)	Facial Axis ^ Basion Nasion
4	Facial Depth (FD)	Facial Plane ^ Frankfort
5	Ramus Height (MP)	Mandibular Plane ^ Frankfort
6	Convexity (C)	Point A - Facial Plane
7	Palatal Plane Position (PPP)	Palatal Plane - Frankfort
8	Posterior Cranial Length (PCB)	Condylion Posterior - PTV
9	Anterior Cranial Length (ACB)	Cranial Center - Nasion
10	Cranial Deflection (Ba-N^FH)	Ba-N ^ Frankfort
11	Position of the Maxilla (Ba-N^N-A)	Basion -Nasion ^ Nasion - Point A
12	Nasal Plane Length (N-A)	Nasion - Point A
13	Divine Facial Height (A-Pm)	Point A - Protuberance Menti
14	Mandibular Ramus Horizontal Position (Xi^FH)	Xi ^ Frankfort
15	Mandibular Ramus Vertical Position (Xi-FH)	Xi - Frankfort
16	Ramus Height (Xi-R3)	Xi - R3
17	Condyle Axis Length (Xi-Co)	Xi - Condylion
18	Corpus Axis Length (Xi-Pm)	Corpus Axis
19	Mandibular Arch (MA)	Corpus Axis ^ Condyle Axis
20	Posterior Position of Occlusal Plane (Xi-OP)	Xi - Occlusal Plane
21	Occlusal Plane Inclination (OP ^ Xi-Pm)	Occlusal Plane ^ Corpus Axis
22	Lower Incisor Position (horizontally) (B1-APo)	Incisor Tip - Dental Plane
23	Lower Incisor Position (vertically) (B1-OP)	Incisor Tip - Occlusal Plane
24	Lower Incisor Inclination (B1^A-Po)	B1 ^ Dental Plane
25	Depth of Lower Arch (B1-B6)	Mesial of the molar B6 - Incisor Tip B1
26	Molar Relation (B6-A6)	Distal of the molar B6 - Distal of the molar A6
27	Upper Molar Position (A6-PTV)	Distal of the molar A6 - PTV
28	Lower Molar Inclination (B6^Xi-Pm)	B6 ^ Corpus Axis
29	Upper Molar Inclination (A6^ANS-PNS)	A6 ^ Palatal Plane
30	Upper to Lower Incisor (A1^B1)	Interincisal Angle
31	Horizontal Incisor Relation (OVJ)	Overjet
32	Vertical Incisor Relation (OVb)	Overbite
33	Lower Lip Protrusion (li-EI)	Lower Lip - Esthetic Line
34	Upper Lip Protrusion (Is-EI)	Upper Lip - Esthetic Line
35	Nose Length (ANS-prn)	Anterior Nasal Spine - Tip of Nose
36	Chin Thickness (Po-ppo)	Pogonion - propogonion
37	Hyoid Position (H-PTV)	Body of the Hyoid - PTV
38	Anterior Facial Ratio (N-ANS/ANS-Me)	N-ANS/ANS-Me
39	Maxillary Length (Co-A)	Condylion - Point A
40	Mandibular Length (Co-Gn)	Condylion - Gnathion
41	Gonial Angle (Co-Go^Go-Me)	Condylion - Gonion ^ Gonion - Menton

**Table 1**

Lateral Cephalometric Analysis

# Foundation for Modern {BIO} progressive Orthodontics

Inaugural Symposium  
September 14 -15, 2012 | Chicago, Illinois

[www.bioprogressive.org](http://www.bioprogressive.org)

## Patients

This study included a total of 77 patients. The total control group (TCG), 37 patients, did not receive any appliance; they were followed for 1.62 years (Table II); the remaining 40 patients (Table III) were treated by Ricketts orthopedic Class II therapy<sup>46-48</sup> (TTG). The total control group (TCG) patients were selected from the files of the Department of Orthodontics, University of Florence, and consisted of 18 males and 19 females with a mean age of 8.55 years (range 7.58-10.83), in mixed dentition at T1. The other 40 (TTG), 19 males and 21 females, with a mean age of 8.86 years (range 7.43-10.25), in mixed dentition, were treated for 1.55 years, followed for 1.98 years and collected from a single orthodontic practice where the Bioprogressive therapy is used. The skeletal age of both groups corresponding to a pre-puberty stage (CVMSI) was assessed on lateral cephalograms of the examined subjects according to the cervical vertebral maturation method.<sup>49</sup> In order to evaluate the effects of treatment, differences between the total treated group (TTG) and the total control group (TCG) were identified after treatment (T2). Normal growth changes were obtained by comparing the means at T1 and T2 for the total control group (TCG).

The total treated group (TTG) was divided into 2 subgroups according to the facial type. The open group (OG) consisting of 20 patients, 10 males and 10 females (Table IV), was treated by



n= 37 18 m 19 f				
VARIABLE	Mean	St.Dev.	Min.	Max
Total Facial Height (TFH) <sup>°</sup>	62.41	5.10	48.00	74.00
Lower Facial Height (LFH) <sup>°</sup>	46.00	4.19	33.00	54.00
Central Facial Direction (FAX) <sup>°</sup>	87.68	3.09	81.00	95.00
Facial Depth (FD) <sup>°</sup>	86.73	3.92	80.00	99.00
Ramus Height (MP) <sup>°</sup>	27.54	4.76	19.00	39.00
Convexity (C)mm	6.20	1.38	4.00	9.00
Palatal Plane Position (PPP) <sup>°</sup>	-1.92	3.16	-8.00	5.00
Posterior Cranial Length (PCB)mm	28.54	2.57	23.50	33.50
Anterior Cranial Length (ACB)mm	54.76	2.89	49.00	63.00
Cranial Deflection (Ba-N <sup>°</sup> FH) <sup>°</sup>	28.97	2.23	25.00	35.00
Position of the Maxilla (Ba-N <sup>°</sup> N-A) <sup>°</sup>	64.08	2.79	59.00	71.00
Nasal Plane Length (N-A)mm	51.03	4.22	45.00	66.00
Divine Facial Height (A-Pm)mm	43.66	4.32	35.00	55.00
Mandibular Ramus Horizontal Position (Xi <sup>°</sup> FH) <sup>°</sup>	76.07	3.06	70.00	82.00
Mandibular Ramus Vertical Position (Xi-FH)mm	31.97	2.51	26.00	38.00
Ramus Height (Xi-R3)mm	19.97	1.85	17.00	26.00
Condyle Axis Length (Xi-Co)mm	35.35	3.62	24.00	43.00
Corpus Axis Length (Xi-Pm)mm	59.62	3.93	54.00	70.00
Mandibular Arch (MA) <sup>°</sup>	25.27	4.81	17.00	36.00
Posterior Position of Occlusal Plane (Xi-OP)mm	31.97	2.51	26.00	38.00
Occlusal Plane Inclination (OP ^ Xi-Pm) <sup>°</sup>	21.78	4.45	12.00	36.00
Lower Incisor Position (horizontally) (B1-APo)mm	0.62	2.57	-4.00	8.00
Lower Incisor Position (vertically) (B1-OP)mm	2.01	1.47	0.00	6.00
Lower Incisor Inclination (B1 <sup>°</sup> A-Po) <sup>°</sup>	21.54	7.15	3.00	35.00
Depth of Lower Arch (B1-B6)mm	24.78	2.12	20.00	29.00
Molar Relation (B6-A6)mm	0.92	1.61	-3.00	3.00
Upper Molar Position (A6-PTV)mm	12.41	3.44	0.00	20.00
Lower Molar Inclination (B6 <sup>°</sup> Xi-Pm) <sup>°</sup>	104.78	17.94	6.00	118.00
Upper Molar Inclination (A6 <sup>°</sup> ANS-PNS) <sup>°</sup>	105.73	5.54	90.00	115.00
Upper to Lower Incisor (A1 <sup>°</sup> B1) <sup>°</sup>	125.24	12.63	104.00	158.00
Horizontal Incisor Relation (OVJ)mm	5.88	2.41	2.00	12.00
Vertical Incisor Relation (OVV)mm	1.50	2.45	-4.00	6.00
Lower Lip Protrusion (li-E)mm	1.39	3.09	-4.00	8.00
Upper Lip Protrusion (ls-E)mm	0.43	1.95	-4.00	3.00
Nose Length (ANS-prm)mm	20.57	2.17	15.00	25.00
Chin Thickness (Po-ppo)mm	9.76	2.30	6.00	20.00
Hyoid Position (H-PTV)mm	0.53	6.69	-13.00	17.00
Anterior Facial Ratio (N-ANS/ANS-Me)%	0.92	0.08	0.80	1.11
Maxillary Length (Co-A)mm	81.23	4.55	72.00	93.00
Mandibular Length (Co-Gn)mm	97.88	6.22	89.00	115.00
Gonial Angle (Co-Go <sup>°</sup> Go-Me) <sup>°</sup>	130.32	4.94	118.00	138.00

n= 40 19 m 21 f				
VARIABLE	Mean	St.Dev.	Min.	Max
Total Facial Height (TFH) <sup>°</sup>	60.86	5.79	37.00	69.00
Lower Facial Height (LFH) <sup>°</sup>	46.14	4.20	38.00	53.00
Central Facial Direction (FAX) <sup>°</sup>	88.06	3.82	79.00	96.00
Facial Depth (FD) <sup>°</sup>	86.62	2.60	80.00	92.50
Ramus Height (MP) <sup>°</sup>	26.61	4.23	17.00	33.00
Convexity (C)mm	6.22	1.50	3.00	10.00
Palatal Plane Position (PPP) <sup>°</sup>	-3.13	2.58	-9.00	4.00
Posterior Cranial Length (PCB)mm	30.40	2.65	24.00	37.00
Anterior Cranial Length (ACB)mm	56.57	2.71	49.00	72.00
Cranial Deflection (Ba-N <sup>°</sup> FH) <sup>°</sup>	29.11	1.93	25.00	34.00
Position of the Maxilla (Ba-N <sup>°</sup> N-A) <sup>°</sup>	64.26	3.20	56.00	70.00
Nasal Plane Length (N-A)mm	53.32	3.44	46.00	61.00
Divine Facial Height (A-Pm)mm	44.79	3.70	36.60	53.20
Mandibular Ramus Horizontal Position (Xi <sup>°</sup> FH) <sup>°</sup>	46.61	4.34	40.00	57.50
Mandibular Ramus Vertical Position (Xi-FH)mm	34.06	3.39	28.50	47.00
Ramus Height (Xi-R3)mm	21.31	1.65	17.28	25.00
Condyle Axis Length (Xi-Co)mm	36.73	4.60	20.00	44.65
Corpus Axis Length (Xi-Pm)mm	62.90	4.10	55.00	72.50
Mandibular Arch (MA) <sup>°</sup>	27.51	3.85	21.50	40.00
Posterior Position of Occlusal Plane (Xi-OP)mm	1.32	2.27	-4.00	7.00
Occlusal Plane Inclination (OP ^ Xi-Pm) <sup>°</sup>	21.26	3.23	12.00	29.50
Lower Incisor Position (horizontally) (B1-APo)mm	1.71	2.23	-2.85	7.00
Lower Incisor Position (vertically) (B1-OP)mm	2.15	1.77	-1.50	6.00
Lower Incisor Inclination (B1 <sup>°</sup> A-Po) <sup>°</sup>	24.67	6.16	10.00	38.00
Depth of Lower Arch (B1-B6)mm	25.58	2.91	18.00	38.00
Molar Relation (B6-A6)mm	1.01	1.79	-3.00	4.75
Upper Molar Position (A6-PTV)mm	13.96	2.73	7.60	21.00
Lower Molar Inclination (B6 <sup>°</sup> Xi-Pm) <sup>°</sup>	110.90	4.70	99.00	119.00
Upper Molar Inclination (A6 <sup>°</sup> ANS-PNS) <sup>°</sup>	105.86	4.46	97.00	116.00
Upper to Lower Incisor (A1 <sup>°</sup> B1) <sup>°</sup>	120.21	7.59	107.00	142.00
Horizontal Incisor Relation (OVJ)mm	5.49	2.61	1.00	12.50
Vertical Incisor Relation (OVV)mm	1.95	2.26	-5.00	5.00
Lower Lip Protrusion (li-E)mm	2.05	2.79	-5.70	7.00
Upper Lip Protrusion (ls-E)mm	0.64	2.32	-4.00	5.00
Nose Length (ANS-prm)mm	20.43	1.83	17.00	24.50
Chin Thickness (Po-ppo)mm	10.18	1.74	5.00	13.00
Hyoid Position (H-PTV)mm	0.50	5.74	-12.00	13.30
Anterior Facial Ratio (N-ANS/ANS-Me)%	0.84	0.10	0.66	1.09
Maxillary Length (Co-A)mm	83.82	4.78	77.00	97.00
Mandibular Length (Co-Gn)mm	101.98	5.80	91.00	115.20
Gonial Angle (Co-Go <sup>°</sup> Go-Me) <sup>°</sup>	127.00	4.42	117.00	135.00

**Table II**  
Total Control  
Group (TCG) at T1

**Table III**  
Total Treated  
Group (TTG) at T1

**Table IV**  
Open Group (OG) at T1

n= 20 10 m 10 f				
VARIABLE	Mean	St.Dev.	Min.	Max
Total Facial Height (TFH)°	61.70	4.92	52.00	69.00
Lower Facial Height (LFH)°	45.95	4.66	38.00	53.00
Central Facial Direction (FAX)°	87.40	4.57	79.00	96.00
Facial Depth (FD)°	85.55	2.53	80.00	90.00
Ramus Height (MP)°	26.45	4.54	17.00	33.00
Convexity (C)mm	5.96	1.24	3.00	8.10
Palatal Plane Position (PPP)°	-3.45	2.48	-9.00	0.00
Posterior Cranial Length (PCB)mm	30.63	2.73	25.50	37.00
Anterior Cranial Length (ACB)mm	56.78	2.75	51.77	62.70
Cranial Deflection (Ba-N^FH)°	29.15	2.16	25.00	34.00
Position of the Maxilla (Ba-N^N-A)°	63.15	3.22	56.00	70.00
Nasal Plane Length (N-A)mm	52.65	2.98	46.00	58.90
Divine Facial Height (A-Pm)mm	44.58	3.93	36.60	53.20
Mandibular Ramus Horizontal Position (Xi^FH)°	45.03	4.23	40.00	54.00
Mandibular Ramus Vertical Position (Xi-FH)mm	33.02	2.45	28.50	38.00
Ramus Height (Xi-R3)mm	20.82	1.73	17.28	24.48
Condyle Axis Length (Xi-Co)mm	36.74	3.10	31.35	44.65
Corpus Axis Length (Xi-Pm)mm	62.21	3.16	55.57	69.00
Mandibular Arch (MA)°	27.55	4.19	23.00	40.00
Posterior Position of Occlusal Plane (Xi-OP)mm	0.94	2.03	-4.00	3.80
Occlusal Plane Inclination (OP ^ Xi-Pm)°	21.15	2.48	17.00	25.00
Lower Incisor Position (horizontally) (B1-A-Po)mm	0.75	1.80	-2.85	3.80
Lower Incisor Position (vertically) (B1-OP)mm	1.60	1.79	-1.50	5.00
Lower Incisor Inclination (B1^A-Po)°	24.85	5.32	15.00	38.00
Depth of Lower Arch (B1-B6)mm	26.11	1.73	23.00	29.00
Molar Relation (B6-A6)mm	2.02	1.75	-1.50	4.75
Upper Molar Position (A6-PTV)mm	13.03	2.30	7.60	17.00
Lower Molar Inclination (B6^Xi-Pm)°	110.00	4.92	9.00	116.00
Upper Molar Inclination (A6^ANS-PNS)°	106.40	3.52	100.00	111.00
Upper to Lower Incisor (A1^B1)°	119.65	6.54	108.00	134.00
Horizontal Incisor Relation (OVJ)mm	6.53	2.36	2.00	12.35
Vertical Incisor Relation (OVB)mm	0.97	2.39	-5.00	5.00
Lower Lip Protrusion (li-E)mm	1.12	2.81	-5.70	6.65
Upper Lip Protrusion (ls-E)mm	0.28	2.01	-3.80	3.30
Nose Length (ANS-prn)mm	20.21	1.80	17.00	22.80
Chin Thickness (Po-ppo)mm	10.54	1.65	7.60	12.35
Hyoid Position (H-PTV)mm	2.06	5.42	-12.00	13.30
Anterior Facial Ratio (N-ANS/ANS-Me)%	0.92	0.06	0.84	1.09
Maxillary Length (Co-A)mm	82.55	4.05	77.20	91.20
Mandibular Length (Co-Gn)mm	100.23	4.66	94.08	115.20
Gonial Angle (Co-Go^Go-Me)°	128.15	4.22	118.00	133.00

cervical traction alone for 1.30 years, then followed for 1.80 years. The deep group (DG) consisting of 20 subjects, 9 males and 11 females (Table V), was treated by cervical traction associated with a lower utility arch for 1.75 years, then followed for 2.13 years. Cephalograms for each patient in all treatment and control groups at T1 and T2 were taken using a standardized protocol. The enlargement factors were similar among radiographic units (about 8%); thus, no correction was made for enlargement in the analysis of the films.

**Treatment Protocol**

Each treated patient wore a large Rickett's face bow, with loops in the outer arch and an elastic neck strap, which delivered a force of 500 grams for no more than 12 hours per day (night time plus some evening hours). The length of the face bow was extended distally to a point just anterior to the tragus before the neck strap was engaged. Bands were positioned on the upper first molar at the marginal ridge; the gingival tube used for the arch bar had 15° of disto-rotation. The arch bar was bent outward at the molar in order to serve as a buccal shield and to allow for lateral expansion. The anterior portion, when placed, lay anterior to the incisors by 1.0 to 1.5 mm; it was placed near the central third of the incisors at the lip embrasure (Stomion). At the first appointment, the arch bar was formed to make it essentially passive on each side, and a 150 gram force was applied.

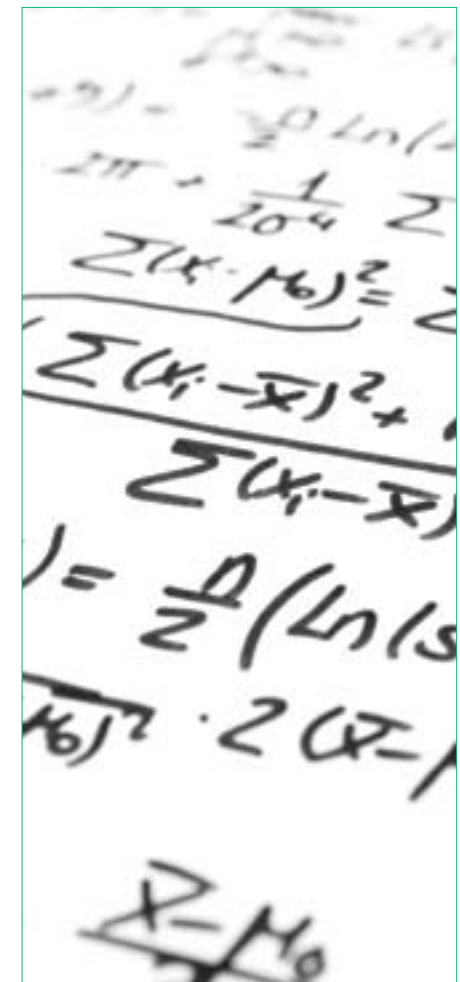
**{ In this way a child is able to place it easily, without pain. }**

After four weeks, then monthly for the wearing period, four adjustment were made: the arch bar was bent for the molar disto-rotation about 2°-3° until the bayonets were parallel to each other, and widened about 3 mm until a first molar expansion was achieved. The arch form was changed from a tapered shape to a more standard or even ovoid shape; the applied force was 500 grams at the point of attachment of the neck strap to the face bow. After a couple of months, the disto-rotation of the molar and the change of the arch form indicated that the arch bar was in contact with the upper incisors, reducing the overjet (OVJ).

In the Deep Group (DG) a lower utility arch was combined with the cervical traction. It was applied on the first molar with the bands placed at the marginal ridge. Bands used were Ricketts 4D with -24° of torque, -5° of tip and -12° of disto-rotation. The lower utility arch was placed with -10° of torque, -5° of toe-in, 10° of tip-back, 5 mm of expansion each side and in the molar section. The tip back produced a force of 60 grams in the anterior section, enabling intrusion of the lower incisors.

**Data Analysis**

Assessment of the error in method using cephalometric measurements was performed using the Dahlberg<sup>60</sup> formula on 50 patients (25 CTG and 25 TTG) selected randomly from the 2 groups. The measurement error for the linear measurements was an average value of 0.47 mm (range 0.3 and 0.67), and 1.5° for the angular measurements.



The starting forms of TCG with TTG, and the OG with the DG were compared. Craniofacial modifications in the treated groups were compared with the growth modifications occurring in the control group. In particular T1 to T2 changes were analyzed to describe the effects of the active therapy. Composites were manually drawn to visualize the starting forms (T1 TCG, TTG, OG and DG), the growth modifications (T2 TCG) and the modifications obtained by treatment (T2 TTG, OG and DG), and the Rickett's superimposition analysis<sup>61</sup> of the composites were performed showing T2 on T1. Mean, standard deviation, and range were calculated for all the groups; in order to show differences between samples, the Student's t-test was performed by using a commercial statistical package (SPSS for Windows, release 10.0.0, SPSS Inc).

**Results: Comparison of the Starting Forms**

In order to assess significant differences between craniofacial starting forms at the time of the first observation, comparisons between the groups at T1 were performed. No statistically significant differences were found in the craniofacial configurations at T1 in the total control group (TCG) when compared with the total treated group (TTG). Whereas, significant differences were found in the 2 subgroups of the total treated group (OG at T1 vs. DG at T1) for vertical dimension, skeletal maxillary protrusion, modest mandibular postero-rotation, open bite and lower dental protrusion; all factors displayed much more in the OG as showed in Table VI.

VARIABLE	Deep Group n=20		Open Group n=20		t-test p
	Mean	St.Dev.	Mean	St.Dev.	
Total Facial Height (TFH)°	60.09	6.49	61.70	4.92	0.3747
Lower Facial Height (LFH)°	46.32	3.84	45.95	4.66	0.7807
Central Facial Direction (FAX)°	88.66	2.97	87.40	4.57	0.2920
Facial Depth (FD)°	87.59	2.30	85.55	2.53	0.0092
Ramus Height (MP)°	26.75	4.04	26.45	4.54	0.8218
Convexity (C)mm	6.45	1.70	5.96	1.24	0.2908
Palatal Plane Position (PPP)°	-3.25	2.25	-3.45	2.48	0.7853
Posterior Cranial Length (PCB)mm	30.18	2.63	30.63	2.73	0.5913
Anterior Cranial Length (ACB)mm	56.39	2.72	56.78	2.75	0.6465
Cranial Deflection (Ba-N^FH)°	29.07	1.74	29.15	2.16	0.8927
Position of the Maxilla (Ba-N^N-A)°	65.27	2.89	63.15	3.22	0.0299
Nasal Plane Length (N-A)mm	53.93	3.78	52.65	2.98	0.2326
Divine Facial Height (A-Pm)mm	44.98	3.57	44.58	3.93	0.7331
Mandibular Ramus Horizontal Position (Xi^FH)°	49.39	9.06	45.03	4.23	0.0564
Mandibular Ramus Vertical Position (Xi-FH)mm	35.00	2.45	33.02	2.45	0.0575
Ramus Height (Xi-R3)mm	21.75	1.47	20.82	1.73	0.0673
Condyle Axis Length (Xi-Co)mm	36.73	5.71	36.74	3.10	0.9927
Corpus Axis Length (Xi-Pm)mm	63.52	4.79	62.21	3.16	0.3047
Mandibular Arch (MA)°	27.48	3.61	27.55	4.19	0.9521
Posterior Position of Occlusal Plane (Xi-OP)mm	1.66	2.46	0.94	2.03	0.3116
Occlusal Plane Inclination (OP ^ Xi-Pm)°	21.36	3.85	21.15	2.48	0.8337
Lower Incisor Position (horizontally) (B1-A-Po)mm	2.59	2.27	0.75	1.80	0.0060
Lower Incisor Position (vertically) (B1-OP)mm	2.66	1.64	1.60	1.79	0.0508
Lower Incisor Inclination (B1^A-Po)°	24.50	6.95	24.85	5.32	0.8567
Depth of Lower Arch (B1-B6)mm	25.09	3.65	26.11	1.73	0.2609
Molar Relation (B6-A6)mm	0.09	1.29	2.02	1.75	0.0002
Upper Molar Position (A6-PTV)mm	14.80	2.86	13.03	2.30	0.0344
Lower Molar Inclination (B6^Xi-Pm)°	111.73	4.44	110.00	4.92	0.2388
Upper Molar Inclination (A6^ANS-PNS)°	105.36	5.21	106.40	3.52	0.4587
Upper to Lower Incisor (A1^B1)°	120.73	8.56	119.65	6.54	0.6517
Horizontal Incisor Relation (OVJ)mm	4.55	2.52	6.53	2.36	0.0120
Vertical Incisor Relation (OVB)mm	2.84	1.75	0.97	2.39	0.0057
Lower Lip Protrusion (li-E)mm	2.89	2.55	1.12	2.89	0.0388
Upper Lip Protrusion (ls-E)mm	0.98	2.57	0.28	2.01	0.3331
Nose Length (ANS-prn)mm	20.64	1.87	20.21	1.80	0.4511
Chin Thickness (Po-ppo)mm	9.84	1.78	10.54	1.65	0.1942
Hyoid Position (H-PTV)mm	-1.13	5.74	2.06	5.42	0.0828
Anterior Facial Ratio (N-ANS/ANS-Me)%	0.76	0.06	0.92	0.06	3.79 <sup>11</sup>
Maxillary Length (Co-A)mm	84.98	5.17	82.55	4.05	0.1004
Mandibular Length (Co-Gn)mm	103.57	6.35	100.23	4.66	0.0614
Gonial Angle (Co-Go^Go-Me)°	125.95	4.44	128.15	4.22	0.1091

**Table VI**  
Open Group (OG) versus Deep Group (DG) at T1

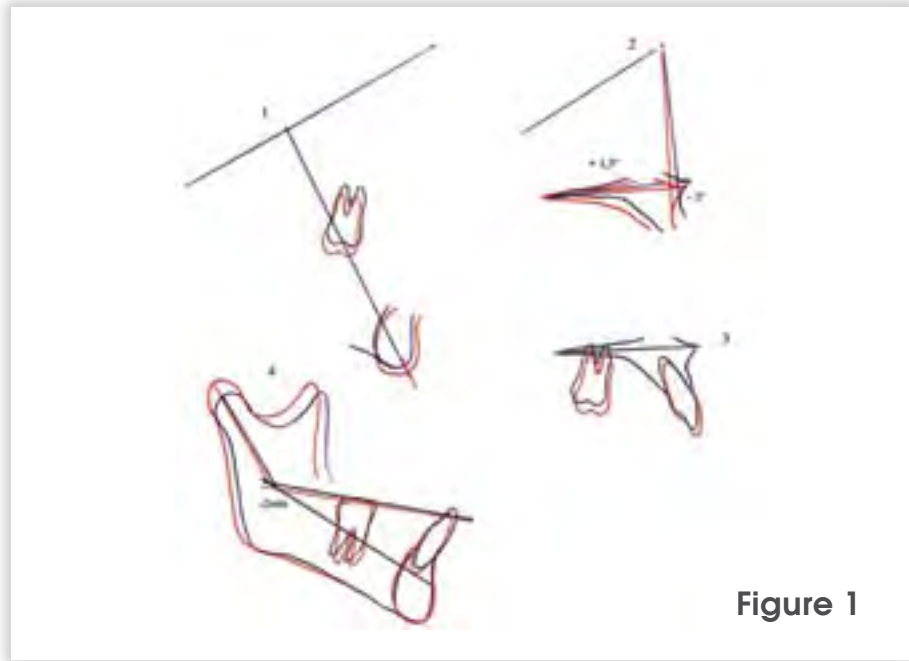


Figure 1

#### The Total Control Group (TCG)

The applicability of the Rickett's superimposition analysis was confirmed by studying the changes that occurred in the total control group (TCG):

Basion-Nasion at Cc. T1= 87.68°; T2=87.20°; t-test: p=0.519. The facial axis doesn't change.

#### Superimposition 2

Basion-Nasion at Nasion registered at A point (Basion-Nasion, Nasion-A). T1= 64.08°; T2=63.46°; t-test: p=0.342. The angle Basion-Nasion, Nasion-A doesn't change. The point A moves downward at 1.48 mm per year (t-test: p=0.044).

#### Superimposition 3

Palatal plane (ANS-PNS) registered at ANS. The upper denture moves forward 0.3 mm per year. The molar erupts 0.7 mm per year. The incisor erupts 0.4 mm per year.

#### Superimposition 4

Mandibular corpus axis (Xi-Pm) registered at Pm. The molar erupts 0.5 mm per year for the long the axis along the mesial cusp. The incisor erupts 0.3 mm per year and goes backward 0.2 mm per year.

The behavior of the maxilla and the mandible as analyzed by McNamara, Baccetti, Franchi is as follows:

The distance Co-A increases at 1.5 mm per year; t-test: p=0.045.

The distance Co-Gn increases at 2.4 mm per year; t-test: p=0.025.

The angle Co-Go-Me decreases at 0.7° mm per year; t-test: p=0.361.

#### The Effect of Treatment (TCG versus TTG)

The superimposition analysis (Figure 1) of the composites (TTG at T2 on TTG at T1) of the total treated group (TTG) visualizes the effects of treatment. The following results were obtained by studying the superimposition analysis of the composites (TCG on TTG at T2), the comparison of the differences of the means (T2-T1), and the t-test of the samples (Table VII).

1. In the total treated group (TTG), the mandible grew downward and forward as happened in the control group (TCG) and the facial axis closed more than the control group (TCG); statistically significant (p=0.041).

2. The correction of the convexity was obtained by a backward and downward movement of the maxilla;

the reduction of the angle Ba-N, N-A was statistically significant (p=4-11): 2.74° in the treated group, and 0.62° in the control group.

3. The upper molar was distalized 1.8 mm and extruded 2 mm: the distance A6-PTV was reduced; statistically significant (p=0.0249). The upper incisor moved distally 1mm.

4. The lower molar was distalized 1 mm and intruded 2 mm, in fact the occlusal plane moved downward; statistically significant (p=0.0004).

Furthermore the length of the mandible was increased 2.39 mm more than the control; statistically significant (p=0.00077). The treatment was as effective in the maxilla as in the mandible that grew downward and forward, without any postero-rotation of the mandible. The orthopedic therapy influenced both the teeth and the profile; in several cases class correction was obtained. The inclination of the occlusal plane downward and backward was also responsible for reduction of protrusion of the lower incisors.

#### The Difference in Treatment (OG versus DG)

The application of a lower utility arch in patients with a deep bite and double protrusion was the therapeutic difference between the two groups. Differences were statistically significant (p<0.05) due to treatment, particularly in the DG, and are reported in Table IX:

1. The anterior cranial base grew more (p=0.048).
2. The lower incisor was intruded (p=7.25-05).
3. Arch length was increased (p=0.0117).
4. Class II correction did not occur (p=2.31-07).
5. The lower molar inclined more distally (p=1.72-06).
6. The OVJ was not reduced as in the OG (p=0.002).
7. The overbite (OVb) was corrected (p=0.002).

Table VII  
Treatment  
Changes T2-T1 in  
the Total Control  
Group (TCG)

VARIABLE	T2-T1	t-test: p	Variation per year
Total Facial Height (TFH)*	-0.27	0.811	-
Lower Facial Height (LFH)*	-0.43	0.630	-
Central Facial Direction (FAX)*	-0.47	0.519	-
Facial Depth (FD)*	-0.16	0.840	-
Ramus Height (MP)*	-0.45	0.688	-
Convexity (C)mm	-0.21	0.331	-
Palatal Plane Position (PPP)*	-0.08	0.919	-
Posterior Cranial Length (PCB)mm	0.89	0.144	0.6
Anterior Cranial Length (ACB)mm	1.13	0.110	0.8
Cranial Deflection (Ba-N^FH)*	0.49	0.323	-
Position of the Maxilla (Ba-N^N-A)*	-0.62	0.342	0.4
Nasal Plane Length (N-A)mm	2.11	<b>0.044</b>	1.5
Divine Facial Height (A-Pm)mm	1.38	0.178	1
Mandibular Ramus Horizontal Position (Xi^FH)*	-0.7	0.924	0.5
Mandibular Ramus Vertical Position (Xi-FH)mm	1.39	<b>0.027</b>	1
Ramus Height (Xi-R3)mm	0.88	0.44	0.6
Condyle Axis Length (Xi-Co)mm	1.45	0.066	1
Corpus Axis Length (Xi-Pm)mm	2.18	0.025	1.5
Mandibular Arch (MA)*	0.57	0.416	0.4
Posterior Position of Occlusal Plane (Xi-OP)mm	0.07	0.931	-
Occlusal Plane Inclination (OP ^ Xi-Pm)*	-0.16	0.859	-
Lower Incisor Position (horizontally) (B1-Apo)mm	0.34	0.560	-
Lower Incisor Position (vertically) (B1-OP)mm	3.03	0.667	2.1
Lower Incisor Inclination (B1^A-Po)*	0.18	0.641	-
Depth of Lower Arch (B1-B6)mm	0.1	0.863	-
Molar Relation (B6-A6)mm	-0.04	0.913	-
Upper Molar Position (A6-PTV)mm	1.02	0.805	0.7
Lower Molar Inclination (B6^Xi-Pm)*	4.68	0.132	3.3
Upper Molar Inclination (A6^ANS-PNS)*	0.40	0.776	-
Upper to Lower Incisor (A1^B1)*	-5.48	0.52	3.9
Horizontal Incisor Relation (OVJ)mm	-0.03	0.958	-
Vertical Incisor Relation (OVb)mm	0.59	0.325	0.4
Lower Lip Protrusion (li-E)mm	-0.02	0.984	-
Upper Lip Protrusion (ls-E)mm	-0.21	0.627	-
Nose Length (ANS-pr)mm	1.05	0.051	0.7
Chin Thickness (Po-ppo)mm	0.13	0.759	-
Hyoid Position (H-PTV)mm	-1.43	0.111	1
Anterior Facial Ratio (N-ANS/ANS-Me)%	0.02	0.240	-
Maxillary Length (Co-A)mm	2.08	0.052	1.5
Mandibular Length (Co-Gn)mm	3.44	<b>0.025</b>	2.4
Gonial Angle (Co-Go^Go-Me)*	-1.02	0.361	0.7

Table IX  
Treatment  
Changes T2 T1  
Open Treated  
Group (OTG) versus  
Deep Treated  
Group (DTG)

VARIABLE	Open Treated Group (OTG) n=20 T2-T1=1.80 Treat. Time=1.32		Deep Treated Group (DTG) n=20 T2-T1=2.13 Treat. Time=1.75		t-test p	Diff. of treat.
	Media	Dev.St.	Media	Dev.St.		
Total Facial Height (TFH)*	0.45	1.90	0.36	1.61	0.872	-0.09
Lower Facial Height (LFH)*	0.10	1.33	-0.30	2.37	0.508	-0.40
Central Facial Direction (FAX)*	0.10	1.07	0.09	1.36	0.980	-0.01
Facial Depth (FD)*	1.13	1.56	0.95	1.43	0.710	0.18
Ramus Height (MP)*	0.55	2.01	0.52	1.93	0.08	-0.03
Convexity (C)mm	-2.88	0.91	-3.43	1.76	0.205	-0.55
Palatal Plane Position (PPP)*	1.70	1.45	1.61	1.83	0.863	-0.09
Posterior Cranial Length (PCB)mm	0.23	1.44	1.02	1.62	0.095	0.79
Anterior Cranial Length (ACB)mm	0.50	1.16	1.64	2.30	<b>0.048</b>	1.14
Cranial Deflection (Ba-N^FH)*	0.60	1.47	0.41	1.36	0.658	-0.19
Position of the Maxilla (Ba-N^N-A)*	-2.73	1.67	-2.75	1.27	0.955	-0.02
Nasal Plane Length (N-A)mm	3.04	1.56	4.16	2.11	0.0613	1.12
Divine Facial Height (A-Pm)mm	0.70	1.96	0.93	2.46	0.728	0.23
Mandibular Ramus Horizontal Position (Xi^FH)*	-0.13	2.54	0.30	4.18	0.707	0.43
Mandibular Ramus Vertical Position (Xi-FH)mm	2.47	1.81	2.11	2.97	0.635	-0.36
Ramus Height (Xi-R3)mm	0.88	1.28	1.52	1.05	0.08	0.64
Condyle Axis Length (Xi-Co)mm	2.08	2.25	2.34	4.32	0.818	0.26
Corpus Axis Length (Xi-Pm)mm	2.81	2.47	4.25	2.99	0.094	1.44
Mandibular Arch (MA)*	0.38	3.26	0.84	2.71	0.627	0.46
Posterior Position of Occlusal Plane (Xi-OP)mm	-2.00	1.63	-2.61	2.79	0.385	0.61
Occlusal Plane Inclination (OP ^ Xi-Pm)*	2.43	2.17	2.32	2.77	0.887	-0.11
Lower Incisor Position (horizontally) (B1-Apo)mm	1.48	1.58	0.45	2.24	0.094	-1.03
Lower Incisor Position (vertically) (B1-OP)mm	-0.78	1.40	-2.73	1.49	<b>7.25<sup>05</sup></b>	-1.95
Lower Incisor Inclination (B1^A-Po)*	4.00	5.57	7.23	8.39	0.141	3.23
Depth of Lower Arch (B1-B6)mm	0.77	1.08	1.11	3.08	<b>0.0117</b>	0.34
Molar Relation (B6-A6)mm	-4.18	1.91	0.00	2.44	<b>2.31<sup>07</sup></b>	4.18
Upper Molar Position (A6-PTV)mm	0.86	1.71	0.70	2.67	0.823	-0.16
Lower Molar Inclination (B6^Xi-Pm)*	2.25	5.45	16.57	9.60	<b>1.72<sup>04</sup></b>	14.32
Upper Molar Inclination (A6^ANS-PNS)*	-4.85	6.98	-7.93	10.92	0.313	-3.08
Upper to Lower Incisor (A1^B1)*	-2.50	9.40	-3.23	9.10	0.801	-0.73
Horizontal Incisor Relation (OVJ)mm	-3.38	1.83	-1.23	2.40	<b>0.002</b>	2.15
Vertical Incisor Relation (OVb)mm	0.79	1.99	-1.18	1.95	<b>0.002</b>	-1.97
Lower Lip Protrusion (li-E)mm	-0.68	3.41	-1.84	1.64	0.160	-1.16
Upper Lip Protrusion (ls-E)mm	-1.46	3.73	-2.70	1.45	0.151	-1.24
Nose Length (ANS-pr)mm	1.85	2.06	3.11	1.73	<b>0.042</b>	1.26
Chin Thickness (Po-ppo)mm	0.44	0.90	1.00	1.81	0.228	0.56
Hyoid Position (H-PTV)mm	-1.04	6.03	-0.51	5.85	0.707	0.53
Anterior Facial Ratio (N-ANS/ANS-Me)%	0.03	0.05	0.01	0.16	0.657	-0.02
Maxillary Length (Co-A)mm	1.45	3.51	1.11	2.77	0.726	-0.34
Mandibular Length (Co-Gn)mm	5.16	4.00	6.45	4.43	0.314	1.29
Gonial Angle (Co-Go^Go-Me)*	0.13	2.76	-0.66	2.24	0.307	-0.79

Therefore, the effect of a lower utility arch is not just intrusion of the lower incisors. Results show all lower dentitions move backward and downward. What occurred in patients with a deep bite and double protrusion was a downward and backward rotation of the maxilla and an improvement of the profile. Note the superb control of the vertical dimension in both groups.

#### Discussion

To understand the effects that these types of appliances have in the growing patient, it is useful to describe the modifications obtained in different parts of the cranium.

#### Cranial Base

Control data revealed the glenoid fossa (Cp) moved posteriorly 0.88 mm per year. The treated cases show an inhibition of this growth, displaying just 0.65 mm of movement. This result was previously described by Ricketts<sup>46</sup>, who suggested an effect of the cervical strap in the temporal bone.

#### Maxilla

The angle between the Cranial Plane (Ba-N) and the Nasal Plane (N-A) is a superb parameter to evaluate the position of the upper jaw. This angle is constant during the growth. The value of this angle was the same at T1 in the treated patients and in the control group. A statistically significant difference was found between the DG and the OG (p=0.0299); this suggests that at T1, the DG presented greater upper protrusion than OG. A statistically significant decrease of the Ba-N, N-A angle was found in the treated cases (p=4-11), while no statistically significant difference was revealed between DG and OG. A statistically significant increase of the length of the nasal plane (p=6.9-5) shows tipping of the palatal plane during distalization of the maxilla. This is one of the factors responsible for bite closure, emphasizing the role of a utility arch in deep bite cases. Anterior interference is one of the causes of the mandibular postero-rotation during the overjet (OVJ) correction by any type of mechanics.



## Mandible

The facial axis is used to describe growth and chin behavior. No difference was found for the value of the FAX (88°) at T1 in the treated patients and the control group, and a difference of 1° was found between the DG (86.66°) and the OG (87.40°). During growth, the control group presented a slight opening of the mandible (-0.47°); while for the treated patient group, a statistically significant closure of the mandible was found, represented by the value of the facial axis ( $p=0.041$ ) and also of the facial depth ( $p=0.019$ ). These findings, together with the ones used to evaluate the vertical dimension, clearly show the beneficial effect of this therapy to control the vertical dimension. This result is controversial in the literature; it could be explained by the way some clinicians manage cervical head gear and in the mechanics they use for craniofacial treatment. In our opinion the worsening of the vertical dimension that occurs in some patients, as described in the literature, is not due to the direction of the force applied on the upper first molar but is due to wrong application of the appliance. Excessive forces applied, association with the edgewise appliance, lack of retention, correction of the OVJ without prior correction of the OVB, use of the anterior bite plane, and full-time wearing, are the principal causes of increasing vertical dimension by using cervical traction. Few authors used cervical traction alone. This study demonstrates that only an association with a lower utility arch in order to intrude the lower incisors and eliminate anterior interferences is correct.

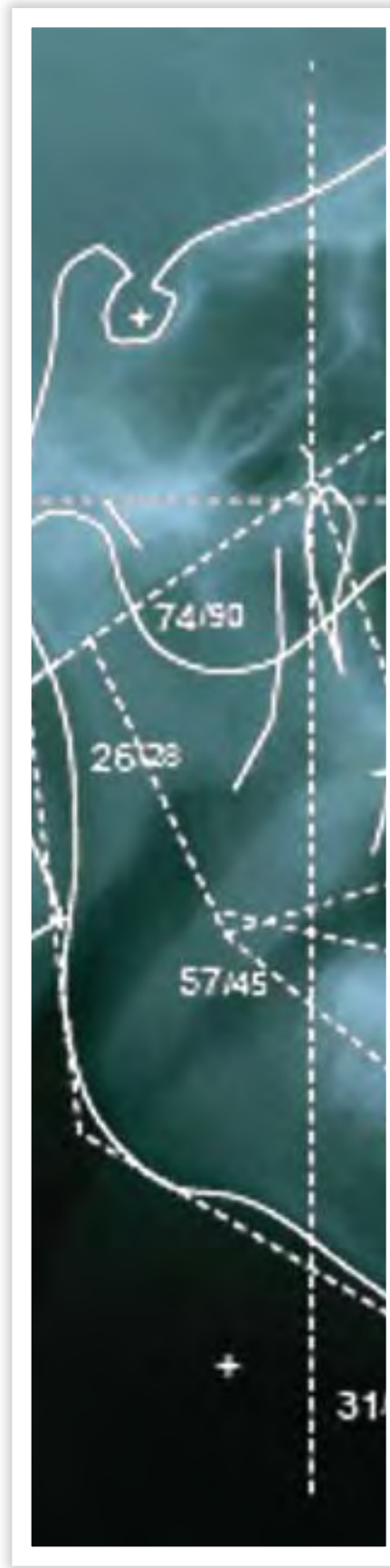Using implants, Björk<sup>62</sup> (1963) confirmed Ricketts's<sup>63</sup> finding reported in 1952. An upward and forward growth of the condyle and ramus was consistent with forward chin development. A more upward and backward growth of the condyle was characteristic of a more vertical increase in facial height. Our findings have strongly suggested that increases in vertical growth of the condyle or even upward and forward growth of the mandibular arch produced by posterior increases, has been consistent with forward

chin development. Ricketts's,<sup>46-48</sup> data compiled by Baumrind<sup>24</sup> in 1981, along with the results of the present study, have given the impression that at least a temporary increase in posterior ramus height and chin position with cervical traction and often molar intrusion is a reality. Histology<sup>64</sup> showed how condyle growth was upward and forward. Scientific evidence suggests that a compression of this area is a cause of mandibular undergrowth. On the other hand, a decompression of this area obtained by an interrupted extrusive force of the upper molar is favorable during Class II correction.

By separately studying the mandible, the beneficial effect of this approach could be seen. A statistically significant increase ( $p=0.007$ ) of the distance Xi-Co in the treated patients was found. Ricketts<sup>55</sup> showed the golden proportion between the distance Xi-Co and Xi-Pm, or equal to 1.618. It is interesting to emphasize that this value was 1.503 in the control group and 1.603 in the treated patients, to show how this approach harmonizes with mandibular growth. Furthermore the total mandibular length increase of 2.9 mm is statistically significant ( $p=0.00077$ ), which occurs with some mandibular posturing devices.

## Teeth

The correction of the molar relation and of the OVJ was statistically significant in the TTG and in the OG for the orthopedic effect of cervical traction, and the orthodontic distalization of the molar and the upper incisors by contact with the arch bar. In all groups, the lower incisor moved back, but the distance 1-APo was increased for the simultaneous pulling back point A. Comparing OG with DG, note that in the DG the OVJ and molar relation were not corrected and the arch depth was increased due to the distal action of the lower utility arch in the lower dentition; the OVB was corrected (-1.97 mm;  $p=0.0002$ ) by tip-back given on the molar section of the utility arch, that determined a distal inclination of lower molar without any extrusive effect of the lower molar, as asserted by some authors. Cortical anchorage prevents



molar extrusion and eruption causing a lowering of the occlusal plane (2.61 mm) and a decreasing of the tipping during the therapy. The molar intrusion, or stabilization, was statistically significant in all groups. This means the extrusive effect of cervical traction on upper molars prevents eruption of the lower molar, obtaining almost the same effect as the utility arch. This was seen by others and it has already been described by vertical growth of the mandible

## Soft Tissues

Improvement of the soft tissue was statistically significant in all groups. The increase of the distance ANS-prn is due to the lowering and distalization of the upper jaw. The difference in this value in the DG and in the OG does not currently have an acceptable explanation. The lip protrusion was also decreased in all groups. These findings confirm how the correction of the maxillo-mandibular relation significantly improves facial esthetics.

## Conclusion

Cervical headgear must be considered as an orthopedic device: the maxilla could be moved backward and downward; the modest extrusion of the upper molar could be responsible for incremental growth of the mandible with good control of the vertical dimension.

Our findings agree with Ricketts,<sup>22,23,46-48</sup> Baumrind<sup>24</sup> and others.<sup>24-26,30,31,34-36,38,39,41-45,49,50</sup> We offer the profession a proven technique to manage cervical traction. Further clarification is needed regarding the timing of when to apply this device to achieve beneficial effects on the mandible.

## Acknowledgments

The author wish to thank Prof. Isabella Tollaro for providing access to patients' records and Prof. Mario Caltabiano for scientific support. This article is dedicated to the memory of Professor Robert M. Ricketts.

## REFERENCES

1. Angle EH. The Malocclusion of the Teeth. Angle's system. 7th ed. Philadelphia: The S.S. White Dental Manufacturing Company; 1907.
2. Brodie AG. Facial Patterns. Angle Orthod 1946; 16: 75-87.
3. Oppenheim A. Biologic Orthodontic Therapy and Reality. Angle Orthod 1936; 6: 157-167.
4. Kloehn SJ. Guiding Alveolar Growth and Eruption of the Teeth to Reduce Treatment Time and Produce a More Balanced Denture and Face. Angle Orthod 1947; 17: 10.
5. Poulton DR. A three-year survey of Class II malocclusions with and without occipital headgear therapy. Angle Orthod 1964; 34: 181-93.
6. Sandusy WC. Cephalometric evaluation of the effects of the Kloehn type of cervical traction used as an auxiliary with the edgewise mechanism following Tweed's principles for the correction of Class II, division 1 malocclusions. Am J Orthod 1965; 51: 262.
7. Schudy FF. The Rotation Of The Mandible Resulting From Growth: Its Implication In Orthodontic Treatment. Angle Orthod 1965; 35: 36-50.
8. Meach CL. A cephalometric comparison of bony profile changes in Class II division 1 patients treated with extraoral force and functional jaw orthopaedics. Am J Orthod 1966; 52: 353-70.
9. Jakobsson SO. Cephalometric evaluation of treatment effect on Class II, Division 1 malocclusions. Am J Orthod 1967; 53: 446-56.
10. Poulton DR. The influence of extraoral traction. Am J Orthod 1967; 53: 8-18.
11. Creekmore DT. Inhibition or Stimulation of the Vertical Growth of the Facial Complex, Its Significance to Treatment. Angle Orthod 1967; 37: 285-97.
12. Kuhn R. Control of anterior vertical dimension and proper selection of extraoral anchorage. Angle Orthod 1968; 38: 340-9.
13. Mays RA. A cephalometric comparison of two types of extraoral appliance used with the edgewise mechanism. Am J Orthod 1969; 55: 195-6.
14. Ringenberg QM, Butts W. A controlled cephalometric evaluation of single-arch cervical traction therapy. Am J Orthod 1970; 57: 179.
15. Merrifield L. Directional forces. Am J Orthod 1970; 57: 435-64.
16. Weinberger TW. Extra-oral Traction and Functional Appliances - A Cephalometric Comparison. Br J Orthod 1973; 1: 35-9.
17. Wieslander L. The effect of force on craniofacial development. Am J Orthod 1974; 65: 531-83.
18. Graber TM. Extrinsic control factors influencing craniofacial growth: in McNamara JA. Control mechanisms in craniofacial growth. Monograph 3, Craniofacial Growth Series, Ann Arbor, MI: Center for Human Growth and Development, University of Michigan. 75:100, 1975.
19. Wieslander L. Early or late cervical traction therapy of Class II malocclusions in the mixed dentition. Am J Orthod 1975; 67: 432.
20. Mills C, Holman G, Graber TM. Heavy intermittent cervical traction in Class II treatment: a longitudinal cephalometric assessment. Am J Orthod 1978; 74: 361.
21. Melsen B. Effect of cervical anchorage during and after treatment: an implant study. Am J Orthod 1978; 73: 526-40.
22. Ricketts RM. JCO interviews: Dr. Robert M. Ricketts on Early Treatment. JCO 1979; 13:115-27 Part II.
23. Ricketts RM, Bench RW, Gugino CF, Hilgers JJ, Schulhof RJ. Bioprogressive Therapy. Book 1. Denver CO, USA: Rocky Mountain Orthodontics; 1979.
24. Baumrind S, Korn EL, Molthen R, West EE. Changes in facial dimensions associated with the use of forces to retract the maxilla. Am J Orthod 1981; 80:17-30.
25. Boecler PR, Riolo ML, Keeling SD, TenHave TR. Skeletal changes associated with extraoral appliance therapy: an evaluation of 200 consecutively treated cases. Angle Orthod 1987; 59: 263-70.
26. Cangialosi TJ, Meistrell ME, Leung MA, Yang Ko J. A cephalometric appraisal of edgewise Class II nonextraction treatment with extraoral force. Am J Orthod Dentofacial Orthop 1988; 93: 315-24.
27. Burke M, Jacobson A. Vertical changes in high-angle Class II, division 1 patients treated with cervical or occipital pull headgear. Am J Orthod Dentofacial Orthop 1992; 102: 501-8.
28. O'Reilly MT, Nanda SK, Close J. Cervical and oblique headgear: A comparison of treatment effects. Am J Orthod Dentofacial Orthop 1993; 103: 504-509.
29. Branz S, Johnson BE, Hanz WP, Gomez JA. Evaluation of the vertical forces generated by the cervical biteplate facebow. Angle Orthod 1993; 63: 119-26.
30. Cook AH, Selke TA, BeGole EA. Control of the vertical dimension in Class II correction using a cervical headgear and lower utility arch in growing patients. Part I. Am J Orthod Dentofacial Orthop 1994; 106: 376-88.
31. Loberg EL. Cervical neckgear—villain or savior? Am J Orthod Dentofacial Orthop 1997; 112: 209-220.
32. Ghafari J, Shofar FS, Jacobsson-Hunt U, Markovits DL, Laster LL. Headgear versus function regulator in the early treatment of class II, division 1 malocclusion: a randomized clinical trial. Am J Orthod Dentofacial Orthop 1998; 113: 51-61.
33. Ucem TT, Yuksel S. Effects of different vectors of forces applied by combined headgear. Am J Orthod Dentofacial Orthop 1998; 113: 316-23.
34. Kirjavainen M, Kirjavainen T, Hurmerinta K, Haavikko K. Orthopedic cervical headgear with expanded inner bow in class II correction. Angle Orthod 2000; 70: 317-325.
35. Gandini MS, Gandini LG Jr, Da Rosa Martins JC, Del Santo MJr. Effects of cervical headgear and edgewise appliances on growing patients. Am J Orthod Dentofacial Orthop 2001; 119: 531-9.
36. Kim KR, Muhl ZF. Changes in mandibular growth direction during and after cervical headgear treatment. Am J Orthod Dentofacial Orthop 2001; 119: 522-30.
37. Junkin JB, Andria LM. Comparative Long-Term Post-Treatment Changes in Hyperdivergent Class II Division 1 Patients With Early Cervical Traction Treatment. Angle Orthod 2002; 72: 5-14.
38. Sambataro S. The effects of cervical headgear in a dolichofacial high convexity female subject. The 2nd World Edgewise Orthodontic Congress. Florence; 2003;156.
39. Lima Filho RMA, Lima AL, Carlos de Oliveira Ruelhas A. Mandibular changes in skeletal class II patients treated with Kloehn cervical headgear. Am J Orthod Dentofacial Orthop 2003;124:83-90.
40. Melsen B, Dalstra M. Distal molar movement with Kloehn headgear: Is it stable? Am J Orthod Dentofacial Orthop 2003;123:374-378.
41. Haralabakis NB, Sifakakis IB. The effect of cervical headgear on patients with high or low mandibular plane angles and the 'myth' of posterior mandibular rotation. Am J Orthod Dentofacial Orthop 2004;126:310-7.
42. Ülger G, Arsan T, Sayinsu K, Isik F. The role of cervical headgear and lower utility arch in the control of the vertical dimension. Am J Orthod Dentofacial Orthop 2006; 130: 492-501.
43. LaHaye MB, Buschang PH, Alexander RG, Boley JC. Orthodontic treatment changes of chin position in Class II Division 1 patients. Am J Orthod Dentofacial Orthop 2006;130:732-741.
44. Siqueira DF, Rodrigues de Almeida R, Janson G, Brandão AG, Coelho Filho CM. Dentoskeletal and soft-tissue changes with cervical headgear and mandibular protraction appliance therapy in the treatment of Class II malocclusions. Am J Orthod Dentofacial Orthop 2007;131:447.e21-447.e30.
45. Godt A, Kalwizki M, Göz G. Effects of cervical head gear on overbite against the background of existing growth patterns. Angle Orthod 2007;77:42-46.
46. Ricketts RM. Orthodontic treatment in the growing patient. Vol. I,II,III,IV. Scottsdale AZ, USA: American Institute for Bioprogressive Education and Ricketts Research Library and learning Center, Loma Linda University CA, USA; 1998.
47. Ricketts RM. Stretching the orthodontic mind to new dimensions. Scottsdale AZ, USA: American Institute for Bioprogressive Education and Ricketts Research Library and learning Center, Loma Linda University CA, USA; 2002.
48. Ricketts RM. Extraoral Traction - A Phoenix. Scottsdale AZ, USA: American Institute for Bioprogressive Education and Ricketts Research Library and learning Center, Loma Linda University CA, USA; 2003.
49. Siqueira DF, Rodrigues de Almeida R, Janson G, Brandão AG, Coelho Filho CM. Dentoskeletal and soft-tissue changes with cervical headgear and mandibular protraction appliance therapy in the treatment of Class II malocclusions. Am J Orthod Dentofacial Orthop 2007;131:447.e21-447.e30.
50. Godt A, Kalwizki M, Göz G. Effects of cervical head gear on overbite against the background of existing growth patterns. Angle Orthod 2007;77:42-46.
51. Baccetti T, Franchi L, McNamara JA. The cervical vertebral maturation method: some need for clarification. Angle Orthod 2002; 72:316-23. 52. Ricketts RM. The evolution of diagnosis to computerized cephalometrics. Am J Orthod 1969; 55: 795-803.
53. Ricketts RM. The value of cephalometrics and computerized technology. Angle Orthod 1972; 42: 179-99.
54. Ricketts RM. Cephalometric Analysis and Synthesis. Angle Orthod 1961; 31: 141-56.
55. Ricketts RM. The Golden Divisor. JCO 1981; 15: 752-9.
56. Ricketts RM. Progressive cephalometrics paradigm 2000. Scottsdale AZ, USA: American Institute for Bioprogressive Education and Ricketts Research Library and learning Center, Loma Linda University CA, USA; 1998.
57. Ricketts RM. Understanding the VTO: its construction and mechanics for execution. Vol. I,II. Scottsdale AZ, USA: American Institute for Bioprogressive Education and Ricketts Research Library and learning Center, Loma Linda University CA, USA; 1999.
58. Ricketts RM. Provocations And Perceptions In Cranio-Facial Orthopedics. 1st ed. Denver CO, USA: Rocky Mountain Orthodontics; 1989.
59. Baccetti T, Franchi L, McNamara Jr, Tollaro L. Early dentofacial features of class II malocclusion: a longitudinal study from the deciduous through the mixed dentition. Am J Orthod Dentofacial Orthop 1997;111:502-509.
60. Dahlberg G. Statistical Methods for Medical and Biological Students. New York, NY: Interscience Publication; 1940.
61. Ricketts RM. A four step method to distinguish orthodontic changes from natural growth. 1975;9:208-228.
62. Björk A. Variations in the growth pattern of the human mandible: longitudinal radiographic study by the implant method. J Dent Res. 1963; 42: 400-11.
63. Ricketts RM. A study of changes in temporomandibular relations associated with the treatment of Class II malocclusion. Am J Orthod 1952; 38: 918-33.
64. Furstman L. The early development of the human temporomandibular joint. Am J Orthod 1963; 9: 672-82.

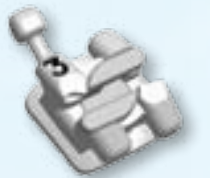Get your  
winning team  
together...



# FLI<sup>®</sup> orthodontic SYSTEMS

## FLI<sup>®</sup> SL

Comfortable rounded profile design  
Quick and easy wire changes  
Optional ligation for finishing  
Easy to open/close



## FLI<sup>®</sup> Twin

Facial, mesial and distal flared lead ins for easy wire insertion and minimal binding  
Low profile design  
Color quadrant for easy identification



## FLI<sup>®</sup> Clear

Ideal clarity to match tooth color  
Small design for patient comfort  
Ideal base construction for great bond strength and easy debonding

## FLI<sup>®</sup> Composite

RMO's new FLI Composite Bracket provides excellent aesthetics in a composite material. Durable to withstand the intraoral environment

## FLI<sup>®</sup> Tubes

Simplifies wire insertion  
Smooth comfortable contours  
Notches for easy positioning



## FLI<sup>®</sup> Wire

Aesthetic wire that will last until your next wire change  
Maintains all of the thermal properties of the Niti wire  
Available in round rectangular and square sizes

## FLI<sup>®</sup> Ceramic Adhesive


Specifically formulated for use with RMO's wide range of clear and ceramic brackets  
Light cure adhesive provides extended working time and quick cure application  
Optimum balance of high strength and easy removal offers enhanced bonding efficiency



GIVE US  
YOUR  
HEART



WE'LL SEND  
YOU OUR  
SOLES



The Colorado Orthodontic Foundation provides orthodontic treatment and education to children from financially challenged families.

Your donation today will help put a beautiful smile on a child's face... and a pair of stunning new season Havaianas on your feet, courtesy of Rocky Mountain Orthodontics.

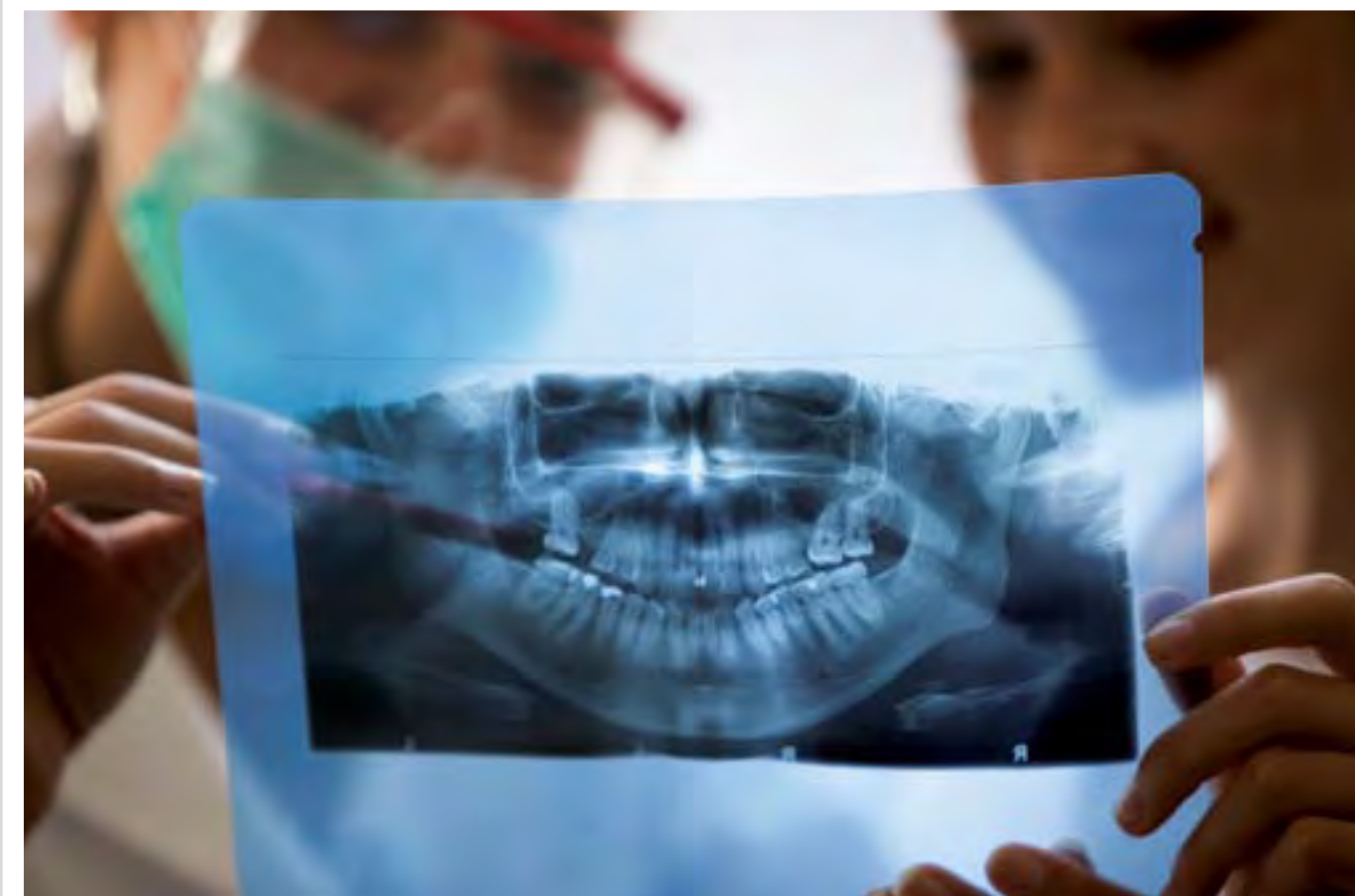To receive your new Havaianas donate now at [www.thecof.org](http://www.thecof.org)

Sponsored by:



## CLASS II CORRECTION WITH SECTIONAL MECHANICS/ DISTALIZATION REVISITED

ENRIQUE GARCÍA ROMERO, DDS



The objective of this article is to refresh some Bioprogressive concepts in the Class II malocclusion treatment, taking into consideration the facial biotype. A contemporary alternative when combined with Dual-Top® ortho-implants (TADs) is presented.

The basic principles of the Bioprogressive technique have a synergistic effect, especially if there are combined in a logic sequence to obtain a solution for the clinical problems.


*"Therefore, changes occur naturally and biologically, without complications."*

The sectional distalization mechanics applied with other principles like: unlocking the malocclusion, using the adequate amount of force to move any tooth and proper treatment planning, allows us to achieve a functional and esthetic result in a conservative way.

The correction of a Class II malocclusion with a continuous arch and Class II elastics produces, in most cases, loss of anchorage with a collateral advance of the lower arch. This occurs because the upper arch is more resistant to the distalization movement due to its greater radicular mass and the cortical palatal bone behind the upper incisors.

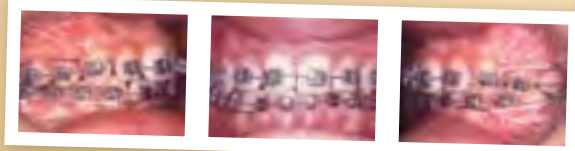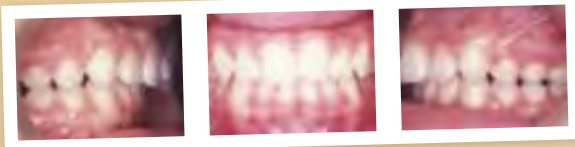The effect of the class II elastics with a continuous arch produces extrusion in the anterior teeth and decreases its torque, it also deepens the bite and produces gummy smile.

Some orthodontic techniques suggest that is impossible or unstable to distalize the buccal segments. This is due, at least in part, because of the use of continuous arch and an incorrect force levels. The clinical Bioprogressive experience has shown that the distalization of the buccal segments is possible and stable in the long term no matter which facial biotype is, as shown in Case #1.



**Case #1:** Long term follow up Class II correction. Male, 11 years old, dolichofacial pattern.

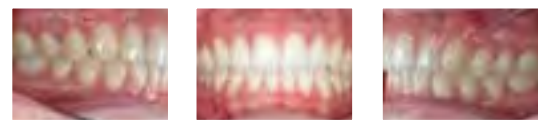- 1) Initial phase extraoral and intraoral photos. Class II malocclusion.
- 2) Orthodontic stage. Class II sectional correction with class II elastics.
- 3) Final orthodontic photos. 13 years old. Treatment time 20 months.



Sectional therapy significantly changed the incidence of need for extractions at all ages. The correct cortical and muscular anchorage, the use of the right force for each facial biotype and the provocation of the normal growth can prevent unwanted vertical changes. The inclination of the occlusal plane should be taken into account in the diagnose and treatment planning; in general, we must avoid the clockwise inclination

of the occlusal plane, especially in the dolichofacial patterns, and achieve the stabilization of the case by lowering the occlusal plane, if possible, below the Xi point in the posterior segment.

Although the Class II division 2 malocclusion is common in the brachyfacial and mesofacial patterns, they can be present in dolichofacials as well.



19 years after treatment intraoral photos. 33 years old. Stable class II correction.

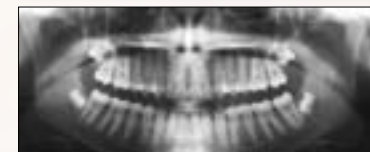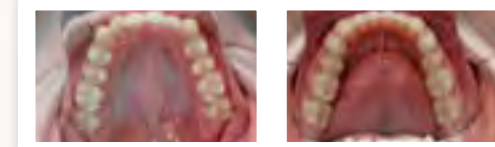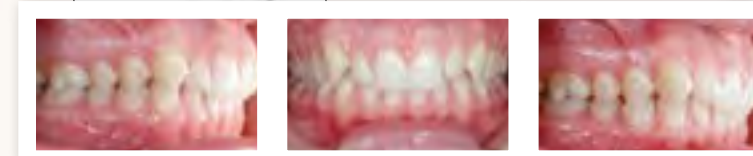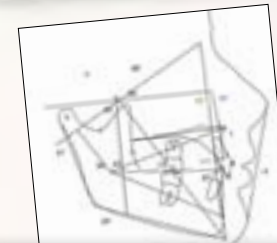


19 years post-retention. 33 years old.




**Case #2:** Female, 14.10 years old, brachyfacial, no gingival exposure, Angle Class II div 2.

Initial phase records. Severe Class II brachyfacial patient with deep bite. She doesn't show gingiva when smiling. Good profile.



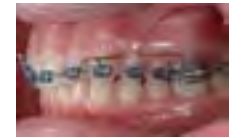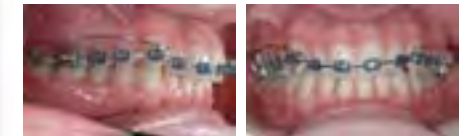In this article we are presenting two summarized clinical examples of Class II division 2 malocclusions, with very different facial biotypes and vertical needs. Case #2 has a brachyfacial pattern with no vertical excess or gummy smile. In this case, the upper incisors intrusion is only temporal, just enough to place the lower brackets. Case #3 has a severe dolichofacial pattern with maxillary

vertical excess and gummy smile (page 40). Thus we have to achieve a greater upper incisors intrusion. In both cases, we must place the upper incisors according to the smile line, for aesthetic purposes. The mechanical differences between these cases are due, in part, from the relationship between the upper incisors and the labial embrasure and the inclination of the occlusal plane.

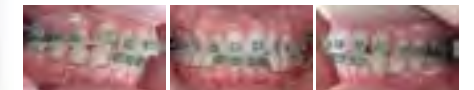

Final facial photographs. 6 months after treatment.

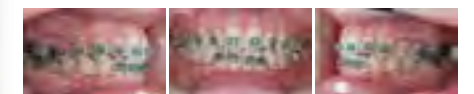**Mechanics**



Unlocking the malocclusion. Torque and incisor intrusion.



Class II buccal correction. Elastics. Sectional mechanics.



Achieving the Class I molar relationship.

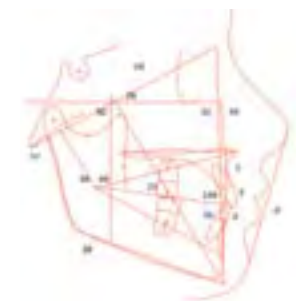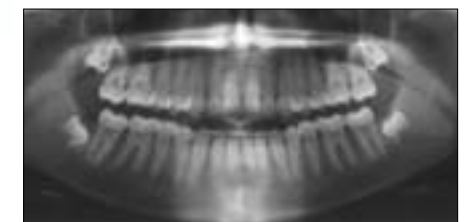


Overcorrection and finishing. Treatment time 16 months.



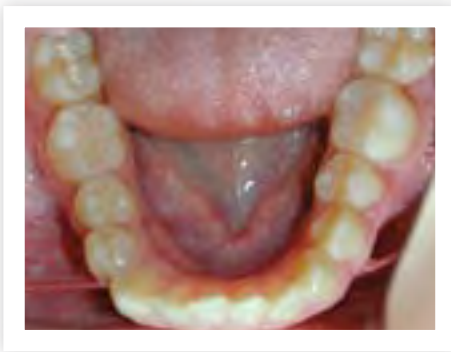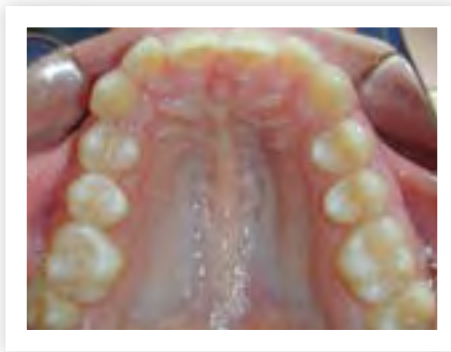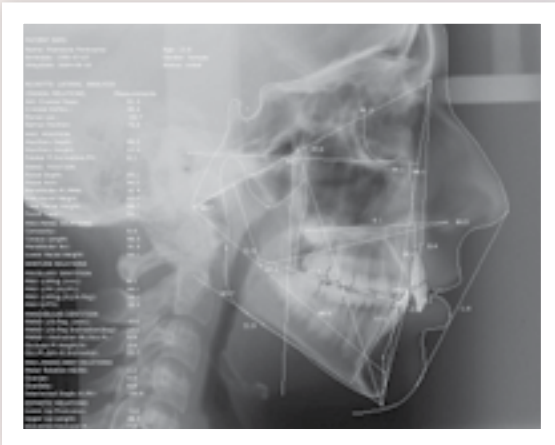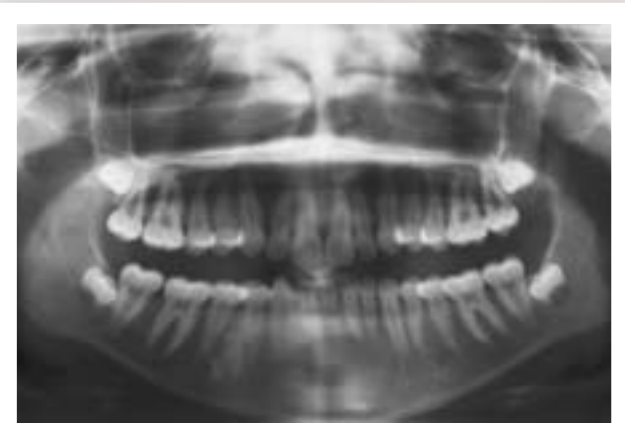6 months post-retention

Final Panoramic X-Ray and Cephalometric analysis.

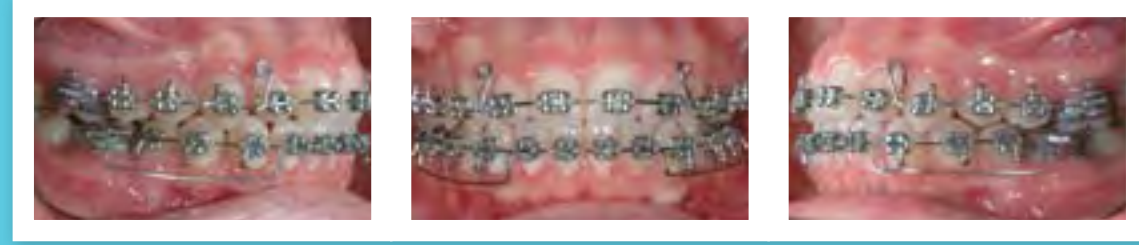
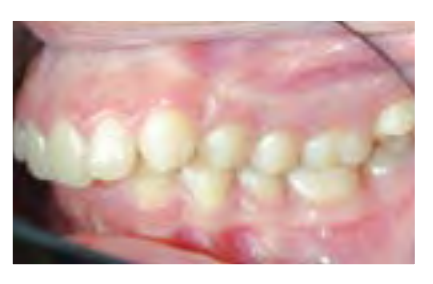
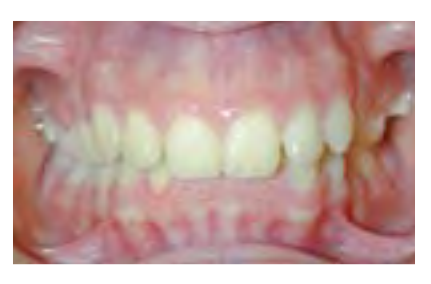
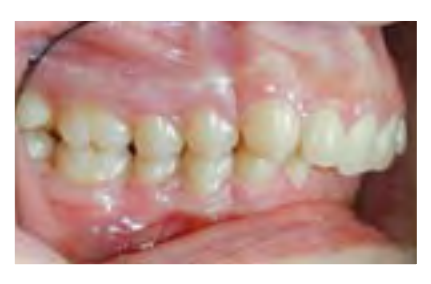
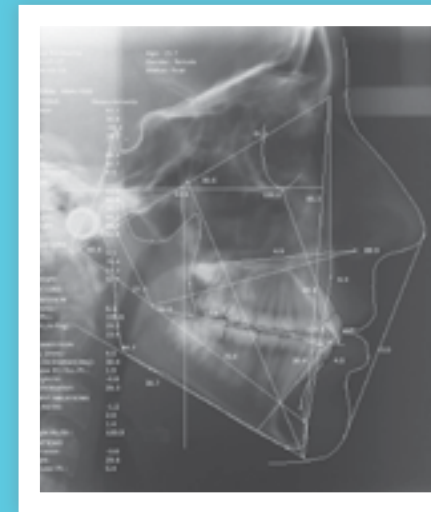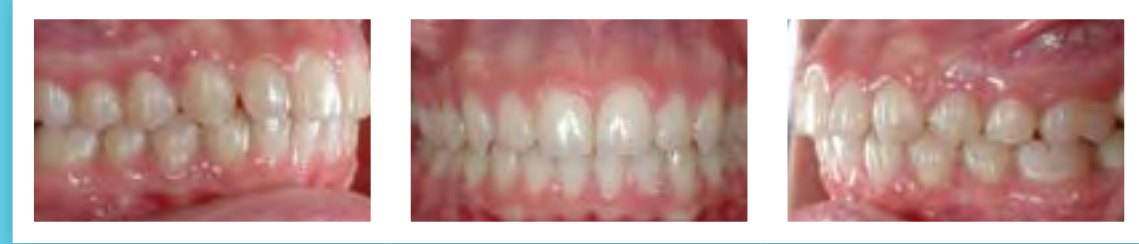**Case #3:** Female, 15 years old, dolichofacial, vertical excess with severe gingival exposure. Angle Class II div 2.



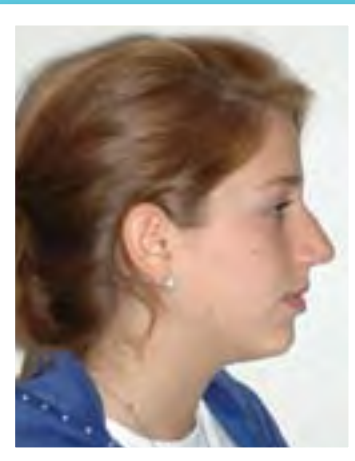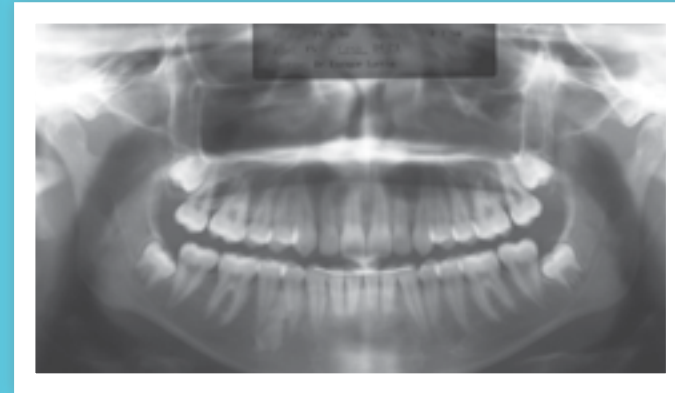Initial records. Notice deepbite and the strong mento-labial sulcus due to the extrusion of the upper incisors.



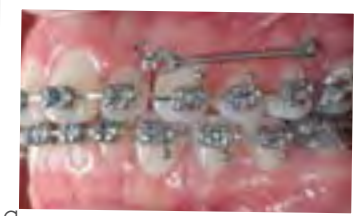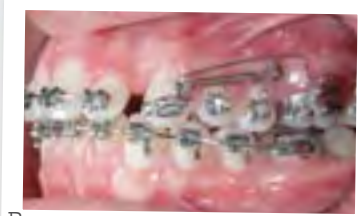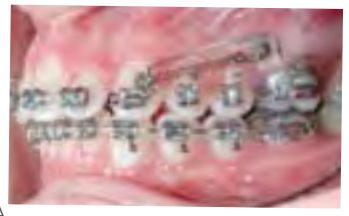Orthodontic final phase. Deepbite correction achieved mainly by upper incisor intrusion with utility arches to correct or improve the vertical anterior excess and gummy smile. The molar class II relationship was corrected with sectional mechanics as in Case #2.



Final records. Notice the improvement of the previous gummy smile and the mento-labial sulcus. Vertical pattern also improved slightly.



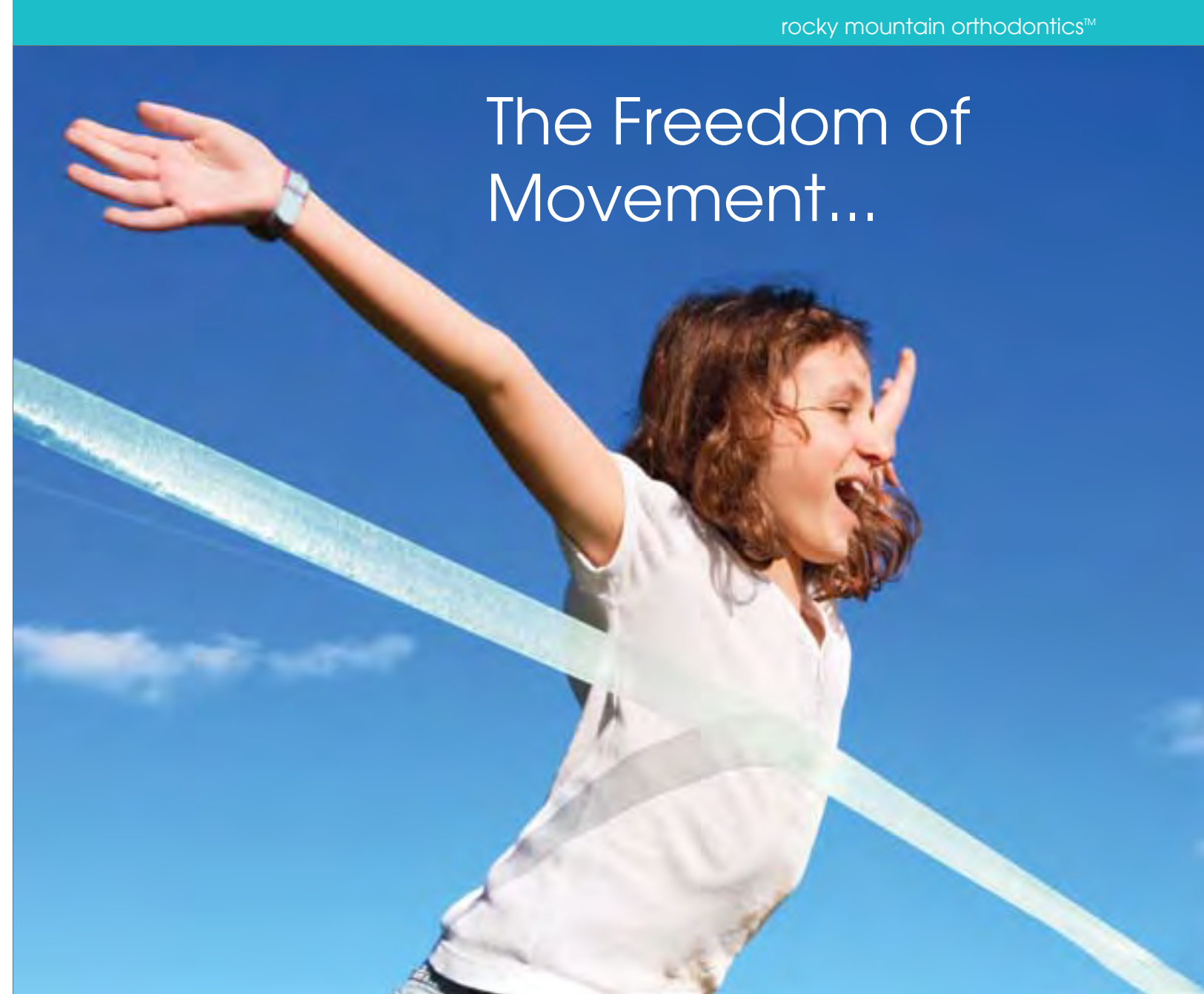Alternative sequence with Dual-Top® anchorage



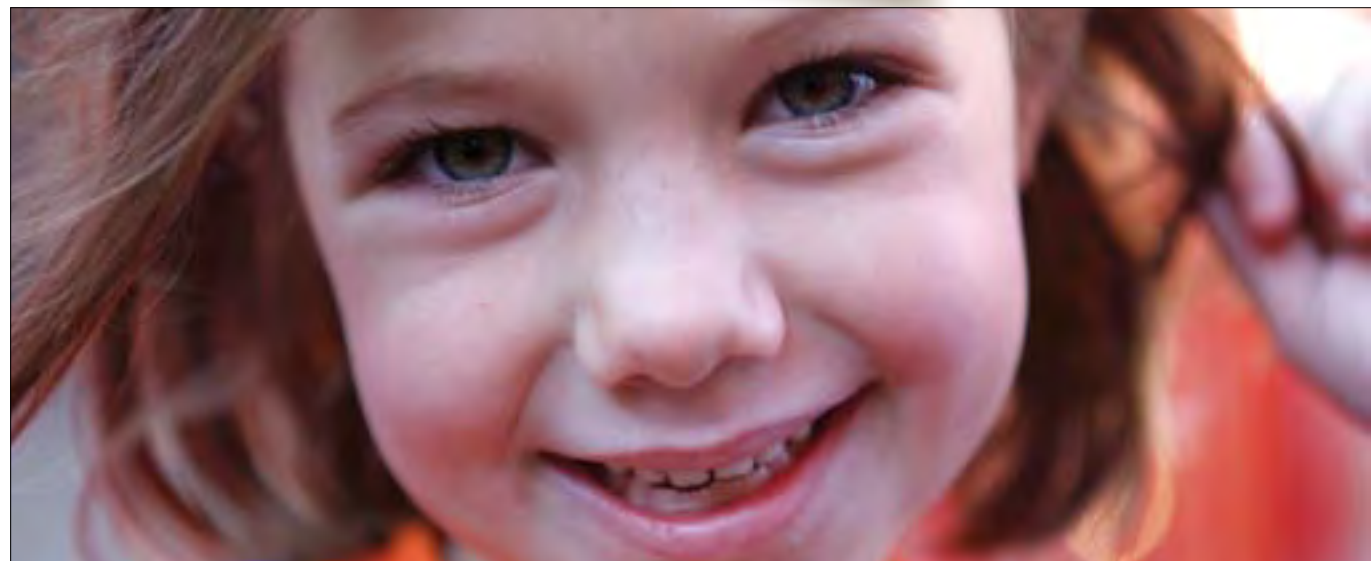Class II correction with ortho-implants. Dual-Top® is placed between second premolar and first molar with NiTi coil spring (A). Notice the amount of distalization in only two months (B). Closing space phase (C). No unwanted vertical anterior side effects.

Sometimes patient cooperation with elastics is poor or you want to avoid its use. In these cases, you can take advantage of Dual-Top® ortho-implants as an excellent anchorage alternative. The following sequence shows how to manage the class II correction with an ortho-implant and NiTi closed coil springs placed on each side.

Conclusion: with careful diagnosis and planning, class II corrections can be achieved by sectional distalization mechanics of the buccal segments. Controlling the vertical side effects with cortical anchorage, along with utilization of the proper force levels according to the biotype, leads to corrections that can be achieved without causing mandibular rotation and other vertical problems.



# The Freedom of Movement...




At RMO® we are still **PASSIONATE** and **COMMITTED** to early treatment...

We encourage you to discover/rediscover all of the early treatment appliances that RMO® has to offer including...

- Liberty Bielle® Fixed Class II Corrector
- Liberty Bielle® Removable Class II Corrector
- Multi-Family® System- Myofunctional Appliances
- Wilson® System- 3D® FIXED/REMOVABLE®

**Liberty Bielle® Fixed**, the newest addition to the RMO® Functional Education® System, is a modern Herbst-type appliance. Its unique ball joint configurations allow it to rotate 360 degrees, which maximizes lateral movement, provides comfort and flexibility for the patient, and ensures treatment efficiency all while minimizing appliance breakage.



## QUAD HELIX INNOVATIONS: POCKET ACES

DUANE GRUMMONS, DDS, MSD

The Quad-Helix appliance is superior to a removable expansion plate in expansion amount, stability, rate and extent of movements with less treatment time.

The Quad-Helix appliance proves effective for increasing widths of intermolar, intercanine, and dentoalveolar regions and for molar derotation. Maxillary arch reshaping is superbly accomplished by gradual and comfortable activations over 6-12 months. The Quad-Helix appliance is superior to a removable expansion plate in expansion amount, stability, rate and extent of movements with less treatment time. Unlocking the malocclusion (Ricketts, Bench, Gugino, Hilgers, Caruso, Sellke, Grummons) typically begins with a Quad.

The Quad-Helix appliance has versatility to reshape arches, correct posterior arch width deficiencies and correct anterior crossbite when auxiliary wires are extended behind the incisor(s). Crossbite corrections are further helped with composite onlay occlusal buildups (turbos) in the lower posterior dentition when indicated.

In aviation, the three planes (pitch, yaw and roll) are well understood. Similarly, the maxillary first molars position in 3 planes can be influenced favorably and differentially by strategic and accurate Quad-Helix activations. Molars can derotate the same on each side, or more on one side than the other. Molars can be extruded, held or intruded. Molars can be expanded on one or both sides and differentially, if prescribed.

The pre-formed Quad-Helix (Rocky Mountain Orthodontics - Ricketts)

when properly activated provides physiologic forces toward treatment objectives of efficient orthodontic treatment. Maxillary transverse changes with use of the Quad-Helix appliance are predictable and impressive. Dental tipping is minimized by lighter and gradual activations. A significant feature is the ability of the quad-helix therapy to re-model the alveolar process of the maxillary component with light and continuous forces during the expansion. (References available upon request.)

### Quad-Helix Considerations

- Age - growing patient
- Facial pattern and transverse norm
- Dentoalveolar maxillary transverse hypoplasia
- Transverse deficiency requirement: Sutural versus dentoalveolar
- Oral hygiene and periodontal conditions favorable



"Utilizing a Quad Helix is like having an ACE up your sleeve."



### Functional Transverse Evaluation

1. Clinical Evaluation
  - a) Facial skeletal features
  - b) Airway – breathing, tongue, etc.
  - c) Musculature – jaw and peri-oral
  - d) Habits – tongue, thumb, etc.
  - e) Parafunction, when evident
  - f) Malocclusion conditions
  - g) Smile esthetics and disharmonies
2. Photos and Models Analysis
 

Inter-molar width, intercanine width, arch perimeter, smile esthetic features
3. Frontal Image
 

Skeletal and dental transverse differentiation  
Asymmetry analysis; coronal/ frontal renderings
4. CBCT-3D Renderings, if indicated

### Denture Unlocking Properties

Typically, a Class II or Class III malocclusion begins with correction of the maxillary width deficiency. Most Class I cases also require transverse increase in arch perimeter. The Quad-Helix is effective in each of these clinical situations.

1. Transverse width - first priority in treatment
2. Vertical control - facial axis management
3. Anterior/posterior sagittal correction achieved

Overexpansion of the maxillary arch width is preferred by 20-30%, followed by a guided intermolar width contraction with rebound to create optimal molar uprighting axial inclinations and transverse stability after the expansion process.

### Quad-Helix Advantages

- In the deciduous, mixed or permanent dentition, the quad provides mild to moderate expansion.
- It also provides for:
  - Reshaping of maxillary arch form
  - Molar derotation (Class II correction)
  - Anchorage and torque control in tandem with archwire
  - Incisors alignment and placement
  - Oral habit correction, when evident
  - Vertical control - tongue influence with slow expansion
  - Ease of placement in one appointment (pre-formed RMO Quad)

Shallow occlusal composites on the functional cusps of lower primary or permanent molars assist by unlocking the malocclusion and clearing defective cuspal inclines. This facilitates a neutral mandible posture as the upper arch Quad-Helix changes occur.

**Quad Activations:**

1. Distal-lateral molar derotation
2. Lingual arm 1-2 mm from premolar teeth as molars rotate disto-laterally
3. Expansion - intermolar width increased; arch perimeter develops
4. Buccal root torque individualized per patient requirements

Activations should be light and intermittent (8-10 weeks) to permit controlled and comfortable movements with least molar tipping. To derotate and/or to distalize molars, it is preferable to adjust one side of the quad to produce desired movement on the opposite side of the arch. This is followed by alternating molar activation on the opposite side of the arch to produce controlled molar movement changes. A midline 3-prong activation increases the arch width.

Transverse widening while primary molars are still in the arch produces additional benefits by remodeling wider alveolar bone for the premolars to erupt into.

A



**Quad-Helix and Variations**

Arch development during the early or late mixed dentition phase, or in the permanent dentition are the preferred timings for Quad-Helix therapy.

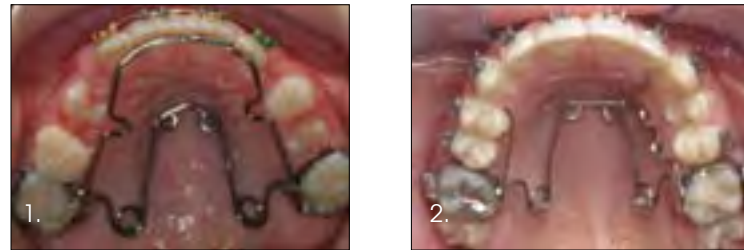
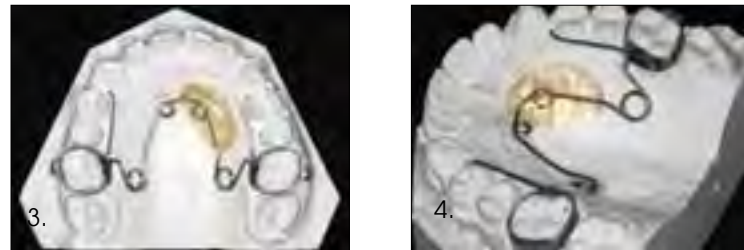
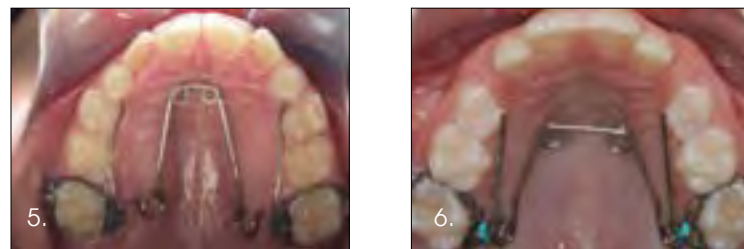
Fig 1: Quad-Helix soldered at molars with sweeps behind the incisors. Fig 2: Quad-Helix with lateral tongue crib to assist in closure of the lateral open-bite from a lateral tongue thrusting condition.



Figs 3, 4: Quad-Helix with asymmetric unilateral palatal acrylic support, which produces greater arch widening on the opposite side.



Figs 5, 6: Pre-formed Quad-Helix (RMO) individualized and inserted into the lingual sheath on each first molar. Quad-Helix with lateral arms to develop arch width of premolars/canines.

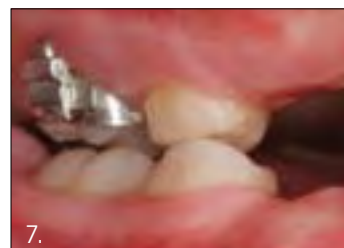
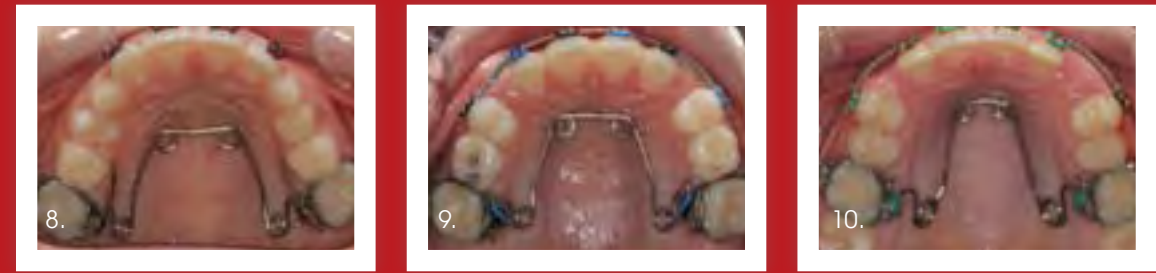
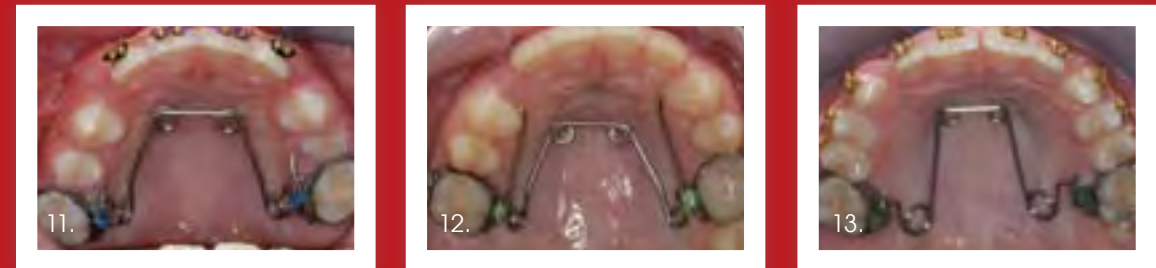Fig 7: Occlusal composite turbo to unlock bite.




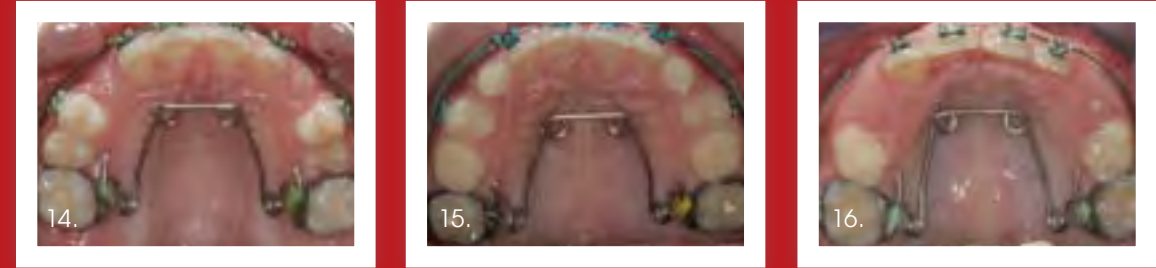
V














Figs 8, 9, 10: The Quad arms can be shortened during treatment.



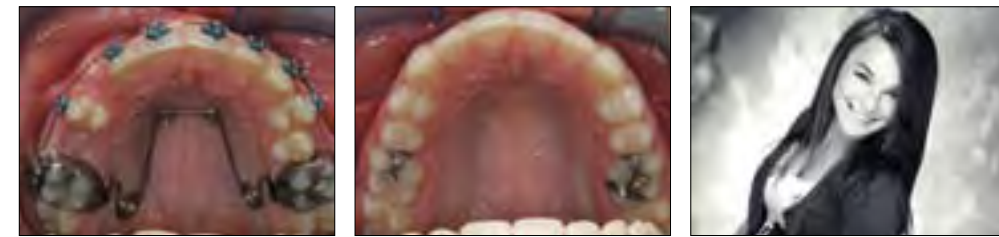Figs 11, 12, 13, 14, 15, 16: Quad-Helix with partial brackets and/or segmental overlay archwire with a utility arch. Generally, the quad is kept in place until the upper premolars and canines are sufficiently erupted.



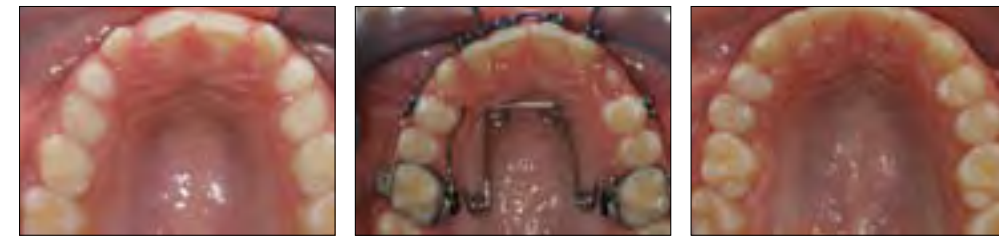

1 ♣		7 ♣	
2 ♣	<p>ROCKY MOUNTAIN ORTHODONTICS WWW.RMORTHO.COM</p> <p>PRE-FORMED QUAD-HELIX REMOVABLE (RICKETS) TRU-CHROME® SS .036 .914 MM</p> <p>CATALOG # A01230 (SIZE 1) CATALOG # A01231 (SIZE 2) CATALOG # A01232 (SIZE 3)</p>	8 ♣	
3 ♣		9 ♣	
4 ♣		10 ♣	
5 ♣		J ♣	
6 ♣		Q ♣	

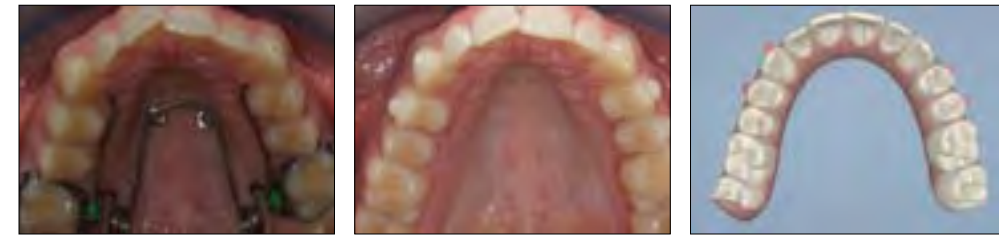- 1 ♣ Rocky Mountain Orthodontics Quad-Helix
- 2 ♣ Quad-Helix order information
- 3 ♣ Size 1 RMO pre-formed quad from package
- 4,5 ♣ Insertion loop adjusted to angle of molar sheath in mouth, and add 5-10 degrees of buccal root torque, and to keep loop away from palatal tissue
- 6,7,8 ♣ Arm bent palatally to ease insertion
- 9 ♣ Midline adjustment to expand at molars
- 10 ♣ 3-prong pliers applies intra-oral adjustment to add expansion
- J ♣ 3-prong can expand or upright molars more
- Q ♣ Well-adjusted Quad-Helix in place



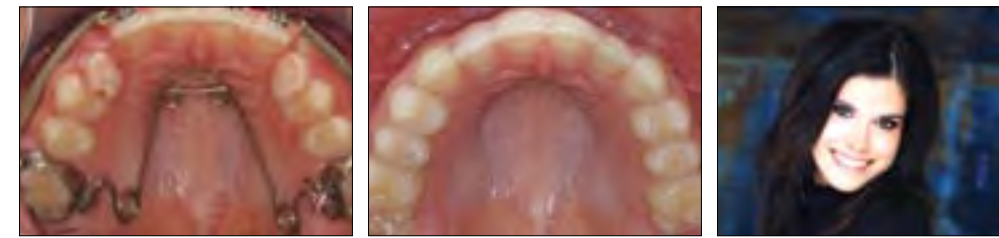**Case Example 1:** Quad-Helix accomplished arch development and optimal molar placement within 8 months. As teeth erupted, brackets were added and a stunning nonextraction result was achieved.



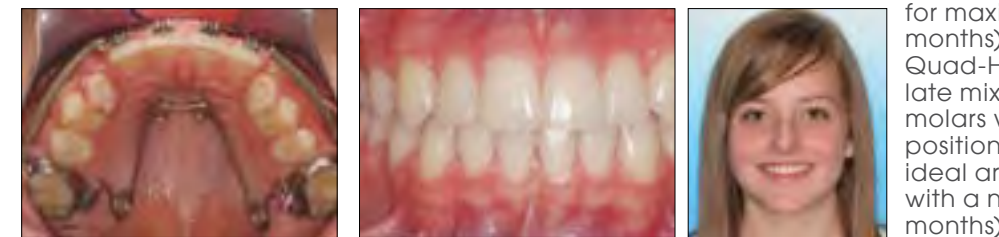**Case Example 2:** Asymmetric Quad with one arm which influences contralateral arch reshaping and widening within 16 months resulting in a symmetric arch perimeter at the finish of treatment.



**Case Example 3:** Typical narrow arch form was expanded within 4 months pre-Invisalign, and made optimal during Invisalign treatment.



**Case Example 4:** Quad without arms created ideal arch form and a balanced esthetic perimeter, with ideal molars 3-D placement. Final smile is stunningly beautiful with great facial harmonies.



**Case Example 5:** Transverse development first with an RPE for maxillary sutural expansion (8 months). A subsequent maxillary Quad-Helix was placed in the late mixed dentition to derotate molars with optimal symmetric positioning, and to establish an ideal arch width. Full brackets with a nonextraction approach (20 months) followed. An exceptional smile and fine esthetic zone were achieved; exceptional treatment goals are evident at the finish.

Grummons Signature Smiles<sup>SM</sup>

# The Lingualjet Appliance

A straight-wire lingual system



Lingualjet™

## A TRIBUTE TO A LOVED DOCTOR

I have to thank RMO for introducing me to Dr. Ricketts. It was a pivotal introduction, one that shaped my professional career and life forward.

As a senior resident at UCLA, I was on my way to take the Tweed course in Tucson, AZ. Overhearing this, Lindy, from RMO pulled me aside quite deliberately, insisting that I would be far better off taking the two week advanced Ricketts course in Pacific Palisades first.

Obstacles included getting the UCLA chairman to agree and for RMR to grant me \$3K scholarship award since I was living off student loans.

The rest is history and the greatest adventure of my life. Dr Ricketts taught me about orthodontics and about life.

In many ways he was a visionary. One example of this was his ability to understand the importance of airway, early interception, and 3D imaging long before current accurate technology was available. Today, 30 years later, we were able, this month, to publish what we hope will be a landmark study....normative data for airway for children through old age. (JOMS June 2012.) Rick gets credit. It was his idea. Similarly with laminography and now we have our 3-D analysis. Later this year we will publish our 3-D simulation VTO with accuracy statistics. I wish Rick was alive to see it all.

Rick always talked about a collaborative practice, a multi-disciplinary approach.

Today we have also build this. His dream became my dream and now a reality in Pacific Palisades (see FaceCenterLa.com) with AAAHC accredited OR on site with recovery, full service laboratory, 3-D imaging and ongoing onsite CE courses for orthodontists and MD's monthly. He even talked about Stem cell and we just received an IRB from Stanford allowing us to perform autologous stromal vascular stem cells therapy on patients in need of regenerative medicine in our facility.

I wish RMR could see it all. He was quite a man.

Richard L Jacobson DMD MS  
 FaceCenterLA | Pacific Palisades

**'The dream of a lifetime.'**



Dr. Robert Ricketts personal impact upon lives remains a flame that burns brightly, and a beacon for learning. Rick inspired us to do small things in great ways, and with newness in thinking, spirit, enthusiasm and interest.  
 Dr. Duane Grummons



Our teacher, our leader, our friend....the man that taught us when you open your heart is when you find your true genius inside. Thank you Dr. Ricketts for setting an example and continuing to feed the minds of so many generations of orthodontists.


With all our love, Gutierrez / Lopez Velarde Family



Dr Ricketts, in addition to his abnormal research capacity, was a great and sweet person. Everyone that had contact with him will never forget him. We all miss his passion for our specialty and every second he dedicated to the non-stop development of the orthodontic science.  
 Dr. Nelson J Oppermann



Dr Ricketts, my mentor, my inspiration, a friend and truly a genius...  
 Dr. Budi Kusnoto



"Ricketts was love, wisdom, strength, art and always a big smile. Unforgettable and unique human being ..."  
 Dr. Enrique Garcia Romero



To me, Dr Ricketts was also a great teacher of life and a model to be inspired to. Dr Ricketts thanks for all you've done for the profession and for making it so exciting.  
 Dr. Sergio Sambataro



"Becoming an active member of the Italian Bioprogressive Society changed my professional life. But the most memorable moment was the karaoke with Bob after the ceremony."  
 Dr. Franco Bruno



## Growing Our FLI Orthodontic Systems...

**FLI** orthodontic  
SYSTEMS



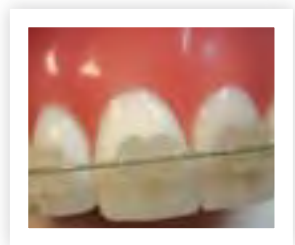
**FLI SL**  
Self Ligating



**FLI TWIN**  
Now in Roth prescription



**FLI CLEAR**



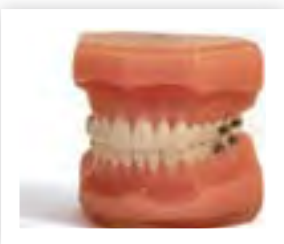**FLI COMPOSITE**



**FLI TUBES**



**FLI MINI 2<sup>ND</sup> MOLAR TUBES**



**FLI WIRE**



**FLI CERAMIC ADHESIVE**